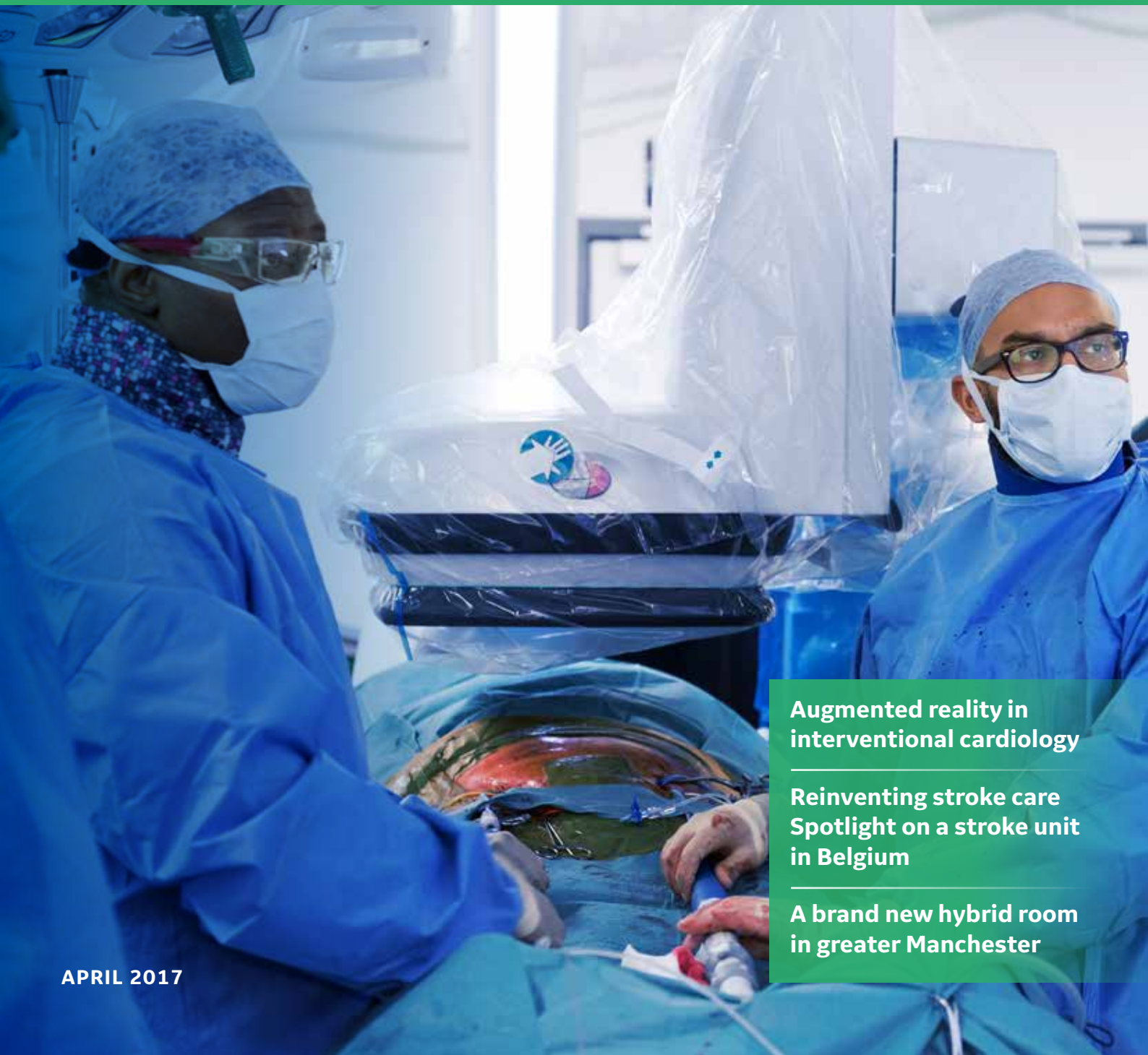



ASSIST

MAGAZINE

Innovative Interventional Treatments

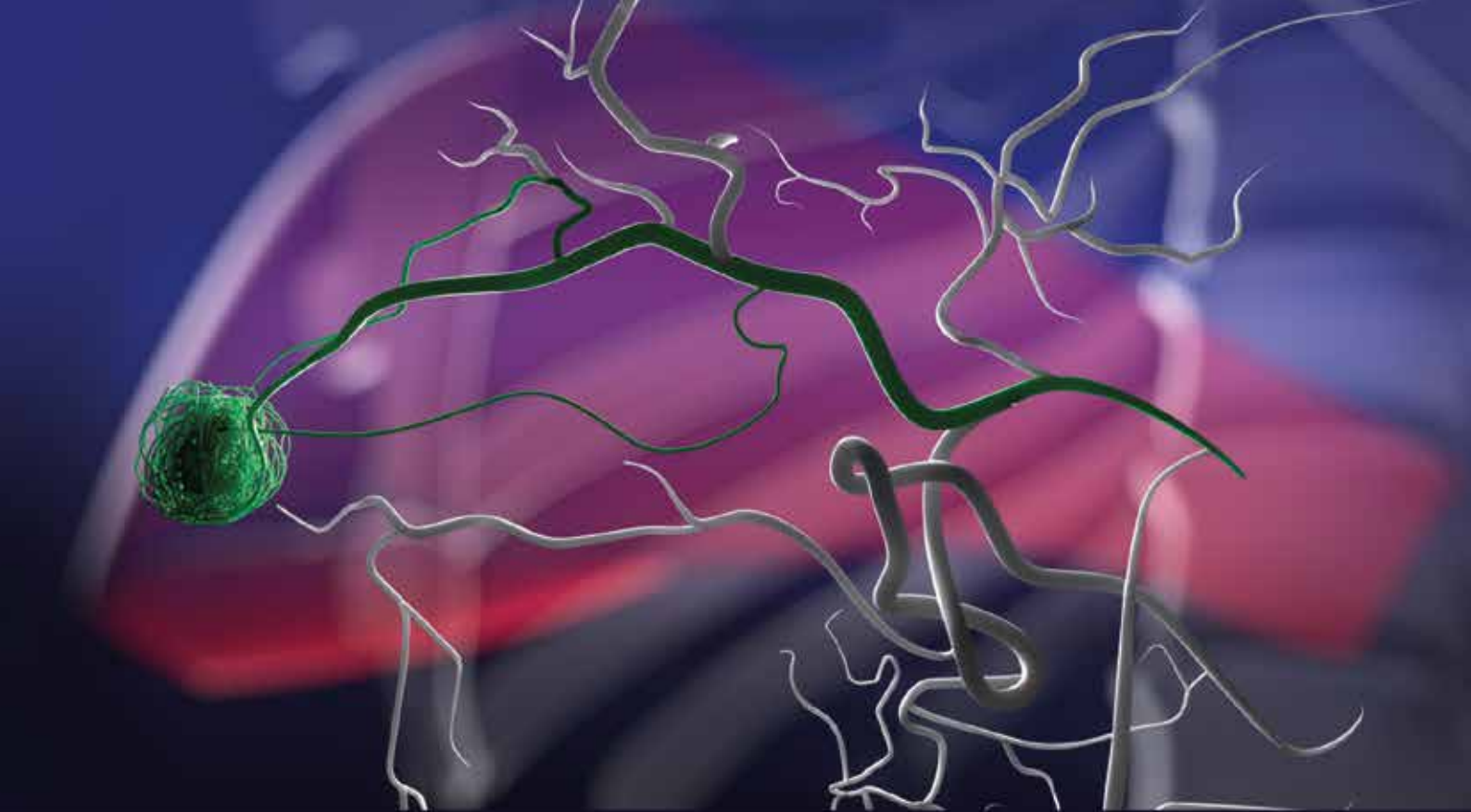


Augmented reality in interventional cardiology

**Reinventing stroke care
Spotlight on a stroke unit in Belgium**

A brand new hybrid room in greater Manchester

APRIL 2017



Power up your clinical decision making with ASSIST

Did you know that 63 % of procedures are powered by ASSIST?*

ASSIST, a collection of 6 interventional imaging software solutions designed for specific clinical subspecialists and for complex endovascular procedures will drive procedure accuracy, dose efficiency and clinical confidence.

Customers using ASSIST acknowledge up to ¹⁶²:

78% contrast reduction

70 % dose reduction (DAP)

28% time reduction

*Based on 15 months of data from 10 clinical sites. Activity screened between April and June 2016

1- Performance obtained from publicly available peer reviewed articles/papers:
http://www3.gehealthcare.com/en/products/categories/interventional_image_guided_systems/assist

2- In clinical use outcomes will vary depending on the system, settings, clinical task, patient size, anatomical location, clinical practice and ASSIST solutions.



Emmanuel Abate
Product Director Europe,
Interventional Guided Systems



Chantal Le Chat
General Manager Global,
Interventional Guided Systems

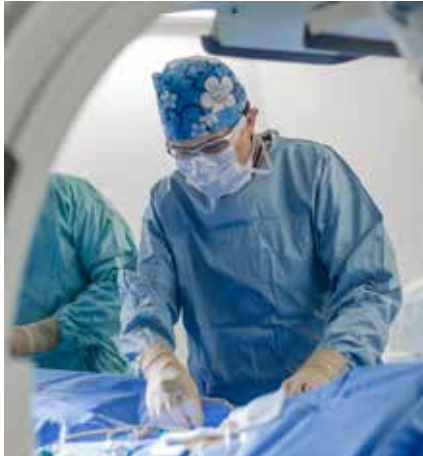Dear reader,

Advances in image guided therapies offer new hope for patients, enabling new treatment options and faster procedures while reducing dose and contrast. In this new ASSIST Magazine, we illustrate how GE Healthcare's advanced visualization tools can help you expand your clinical versatility, successfully perform increasingly sophisticated procedures and make the usage of the imaging system simpler – so that you can focus on the patient.

Whether it be for interventional radiology, neuroradiology, cardiology, or vascular minimally invasive procedures, our philosophy is the same. We partner with leading clinicians to develop image guided solutions that support advancements in clinical practice, and yet remain accessible for routine practice.

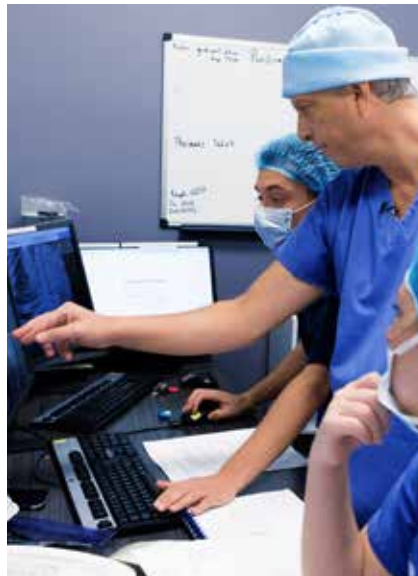We hope you will find this magazine informative. We would also like to take this opportunity to thank our clinical partners for challenging us to develop better tools for patients.

ASSIST MAGAZINE



08 _ Interventional Cardiology

- 08 _ Augmented reality is riding high in cardiac structural interventions, CHU Nantes
- 14 _ How Valve ASSIST helps improve my outcomes for TAVI Interview of Sonia Petronio, Head of Cardiology at Pisa University Hospital
- 16 _ Inverted TAP Technique for a Left Coronary Lesion with PCI ASSIST



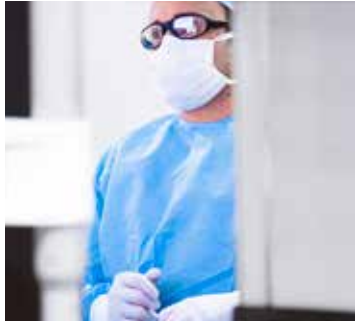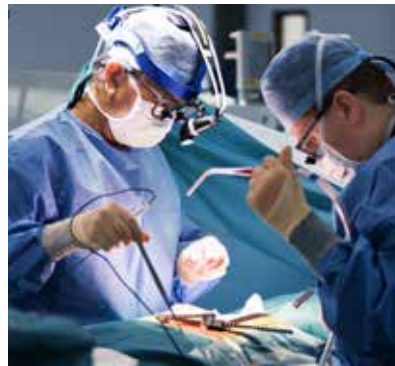19 _ Interventional Oncology

- 19 _ Pushing the boundaries of liver cancer treatment, Jean Verdier University Hospital
- 23 _ Ilio Pubic ramus osteosynthesis and cementoplasty using Needle ASSIST



26 _ Interventional NeuroRadiology

- 26 _ Reinventing stroke care. Spotlight on a stroke unit in Belgium
- 33 _ Acute Ischemic Stroke treatment on Innova IGS 630 in AZ Groeninge



35 _ Interventional Radiology

- 35_ Driving change in the IR department of La Timone University Hospital
- 42_ Zero contrast TEVAR with MRI fusion using Vessel ASSIST

43 _ Vascular Surgery

- 43_ A brand new hybrid room to treat patients in greater Manchester
- 51_ Endovascular Aneurysm Repair with short conical neck on Discovery IGS 730 Maquet using EVAR ASSIST

Local Contact Information:

GE Healthcare Buc
283, rue de la Minière
78533, Buc Cedex, France

Chief Editor:
Dustin Boutboul (dustin.boutboul@ge.com)

Editorial Team: France Schwarz,
Erika Saillant, Cecilia Felix, Philippe Karam,
Thomas Pelon, Bertrand Raulet,
Jean-François Drouet, Miranda Rasenberg,
Emmanuel Abate

Photos: Guillaume Kerhervé,
Arnaud Dhaynaut, Yoan Blanc

Includes text & photographic contributions
from KDM Communications, Le Square,
Olivier Vachey.

English translations: Charles Rogers, Tracy
Deems

Design: Nathalie Ollivier

Printer: Groupe Lecaux Imprimeries
HandiPRINT

Many thanks to our contributors :

Patrice Guérin, MD, PhD, Nantes University
Hospital

Karine Warin-Fresse, MD, Nantes University
Hospital

Anna Sonia Petronio, MD, PhD, Azienda
Ospedaliera di Pisa

Hakim Benamer, MD, La Roseraie Hospital

Olivier Seror, MD, PhD, Jean Verdier Hospital

Lambros Tselikas, MD, Gustave Roussy
Cancer Campus

Olivier François, MD, AZ Groeninge Hospital

Tommy Andersson, MD, PhD, AZ Groeninge
Hospital

Tom Dewaele, MD, AZ Groeninge Hospital

Vincent Vidal, MD, PhD, La Timone University
Hospital

Alexis Jacquier, MD, PhD, La Timone
University Hospital

Donna Young, Director Manager for Surgery
at UHSM

Dare Seriki, MD, UHSM (Manchester)

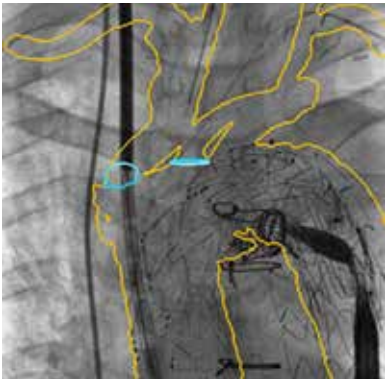
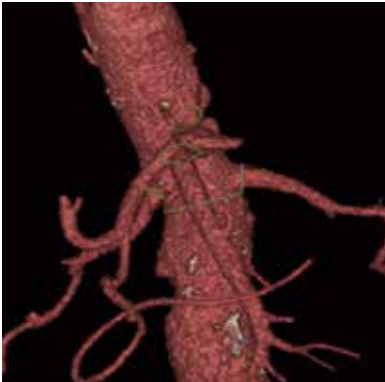
Jonathan Ghosh, MD, UHSM (Manchester)

Isaac Kadir, MD, UHSM (Manchester)



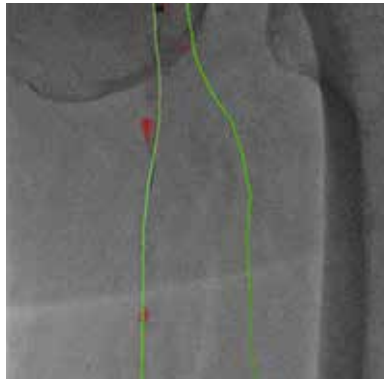
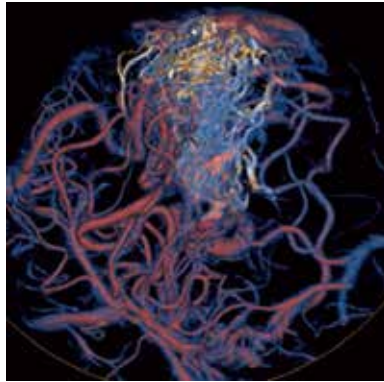
ASSIST Solutions

www.gehealthcare.com/assist



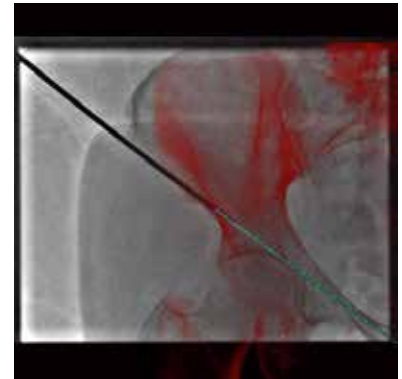
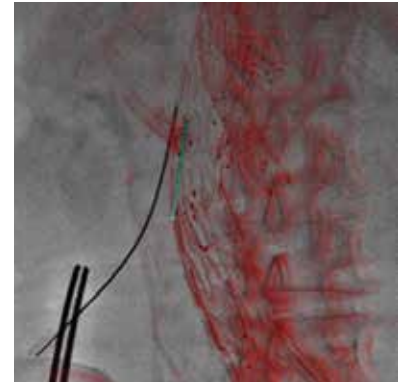
EVAR ASSIST 2 *

Designed by surgeons and interventional radiologists, EVAR ASSIST 2 provides a fully integrated workflow to plan, guide, and assess complex EVAR procedures. EVAR ASSIST 2 consists of a dedicated planning application to acquire and save key anatomical information and measurements for sizing, along with a dedicated image fusion application to provide 3D guidance during the procedure.



VESSEL ASSIST **

Designed by surgeons and interventional radiologists, Vessel ASSIST provides easy to use and accurate planning and guidance tools. For example, Vessel ASSIST enables you to create and edit a vessel centerline, trace through an occlusion, and fuse it on the live fluoroscopy with 2D/3D fusion. This helps reduce the risk of perforations, with 99% radiation dose reduction.¹



Needle ASSIST ***

With Needle ASSIST, you can perform complex percutaneous procedures in the angio room. It provides real-time visualization of needle positions in the 3D space by automatically fusing CBCT data over live fluoroscopic images. This enables precise needle placement, with over 1.8mm accuracy⁵. With the guided-workflow instructions, you can reconstruct a needle in 3D with only two fluoroscopic images in less than 1 minute.⁶

* EVAR ASSIST 2 solution includes FlightPlan for EVAR CT, EVARVision and requires AW workstation with Volume Viewer, Volume Viewer Innova, VesselIQ Xpress, Autobone Xpress. These applications are sold separately. (1)Based on the dose of the procedure step needed using a CBCT acquisition to register pre-operative data vs. a Bi-View registration process. The stated dose reduction does not reflect the entire interventional procedure, rather to a specific step in the procedure.(2) Clinical utility and limitations of tumor-feeder detection software for liver cancer embolization. Iwazawa et al. European Journal of Radiology. 2013. ** VESSEL ASSIST solution includes Vision 2, VesselIQ Xpress, Autobone Xpress and requires AW workstation with Volume Viewer, Volume Viewer Innova. These applications are sold separately. *** NEEDLE ASSIST solution includes TrackVision 2, stereo 3D and requires AW workstation with Volume Viewer, Volume Viewer Innova. These applications are sold separately. (3) Results from a multicentric image review



POWER UP PATIENT CARE

Your patients benefit from greater diagnostic accuracy and therapeutic effectiveness with minimal exposure.



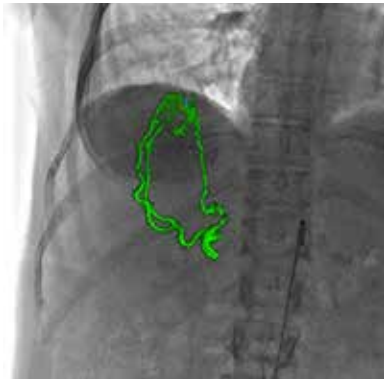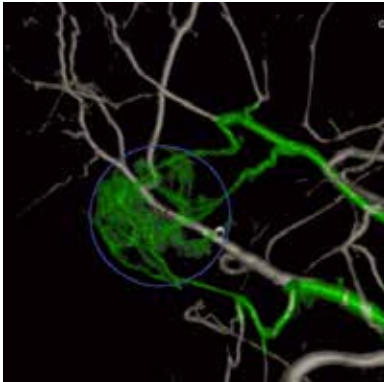
POWER UP YOUR CLINICAL CAPABILITIES AND SERVICE LINE

ASSIST gives you the clinical information to let you plan, guide and assess interventional procedures.



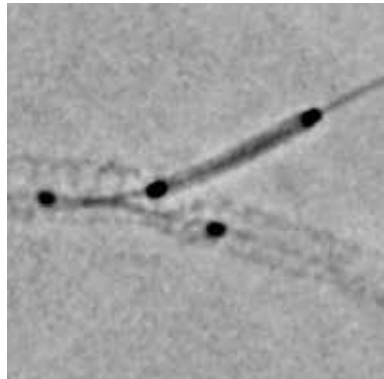
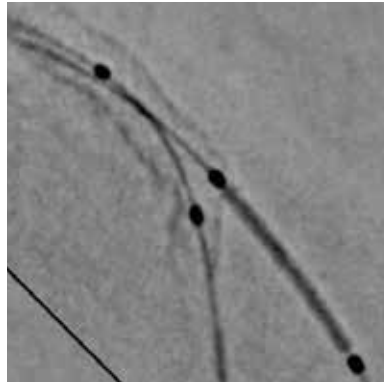
POWER UP PRODUCTIVITY

The ASSIST portfolio provides intuitive planning, designed to make your procedures easier, safer and more efficient.



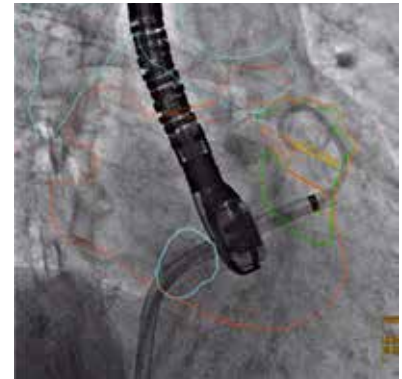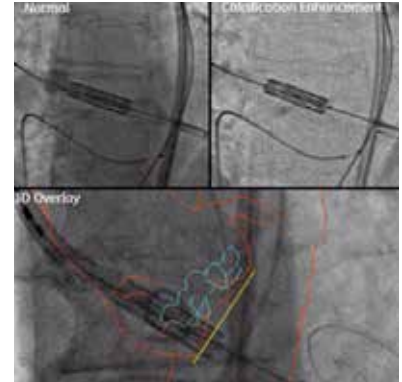
FlightPlan for Liver, an ASSIST brand

FlightPlan for Liver, significantly improves feeder vessels identification, so you can diagnose and perform sophisticated TACE procedures with far greater confidence. Clinical research demonstrates that FlightPlan For Liver delivers superior performance in tumor-feeding vessel identification and inter-operator agreement².



PCI ASSIST ****

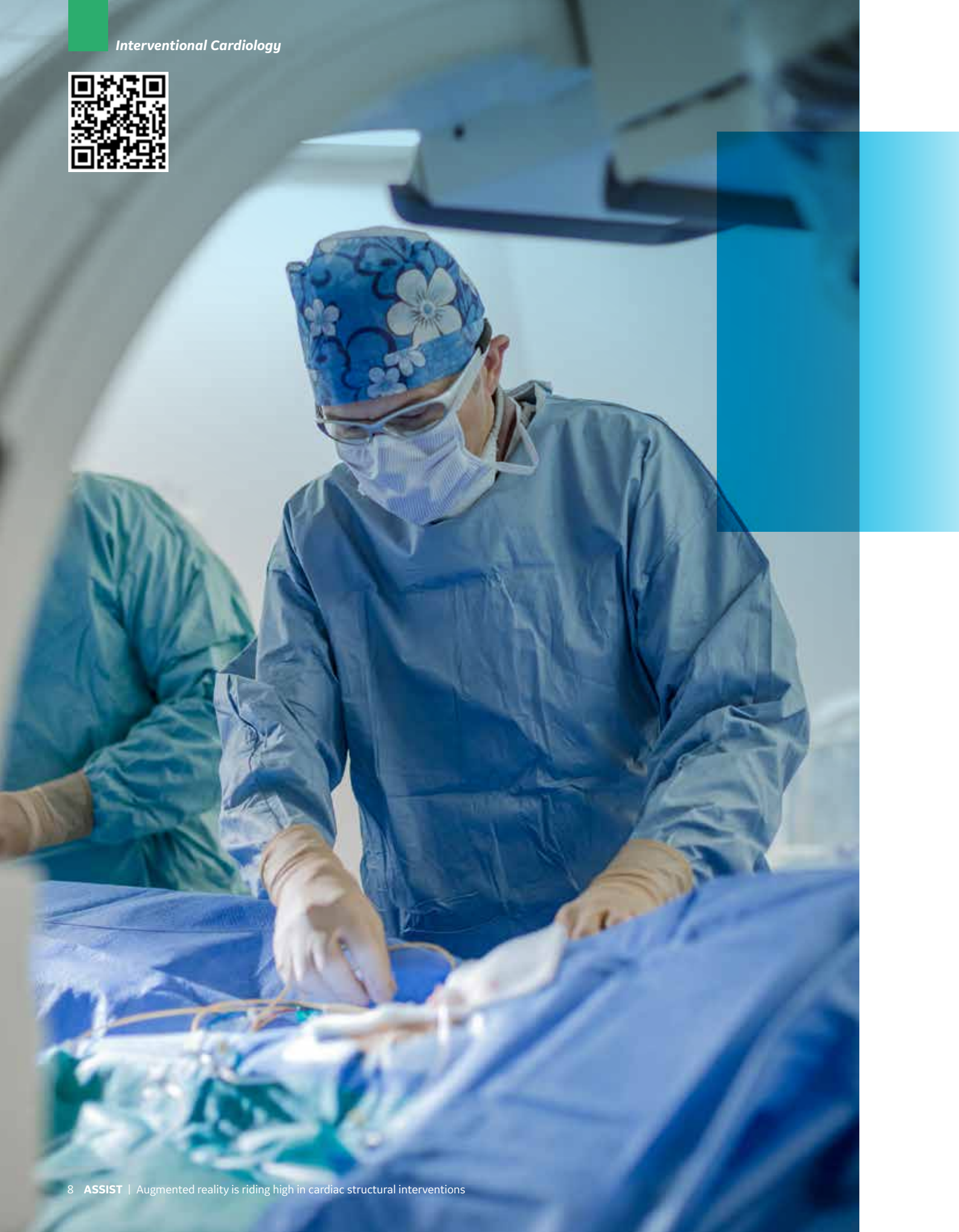Now you can perform long, complex PCI procedures with the same precision and confidence as routine cases – without increasing the dose³. PCI ASSIST significantly helps to improve contrast and visibility. You can clearly see even the smallest details to accurately position and deploy stents thanks to advanced stent visualization softwares. It all adds up to more efficient PCI procedures.



Valve ASSIST 2 *****

Valve ASSIST 2 provides enhanced planning and real-time visualization, enabling you to position the valve and guide devices with extreme precision. New 3D contour rendering further improves intra-aortic visualization. You can choose the appropriate x-ray projection with no use of contrast media and minimal radiation dose.⁴

based on 11 complex PCI clinical cases. (4) Compare to a workflow which does not involve image fusion. (5) The accuracy is defined to be the perpendicular distance between the needle tip in the Stereo 3D image and the shaft of the needle in the CBCT image. This accuracy does not reflect the error in the direction parallel to the needle shaft. The perpendicular accuracy was determined by engineering analysis using rigid phantom data. This idealized accuracy of the Stereo 3D reconstruction is obtained with the 2 fluoroscopic images taken at optimal angulation and without table motion at any step of the reconstruction procedure. (6) Time to reconstruct the object may vary depending on user experience and case complexity. **** PCI ASSIST refers to features of Innova IGS 520, Innova IGS 530 and Discovery IGS 730. ***** VALVE ASSIST 2 solution includes TAVI Analysis, HeartVision 2 and requires AW workstation with Volume Viewer, Volume Viewer Innova. These applications are sold separately.



Augmented reality is riding high in cardiac structural interventions

The development of new imaging technologies, such as image fusion, is helping to fuel a revolution in interventional cardiology. To perform such minimally-invasive surgeries, it is necessary to develop innovative devices and effective imaging tools that help improve the precision of the procedures and, consequently, patient safety. Here is an overview of interventional cardiology practice at the Nantes University Hospital.



A multidisciplinary team for structural heart procedures at Nantes University Hospital. From left to right : Pr Guérin, Dr Boiffard (La Roche sur Yon Hospital), Dr Warin-Fresse and Dr Letreudic (Echographer)

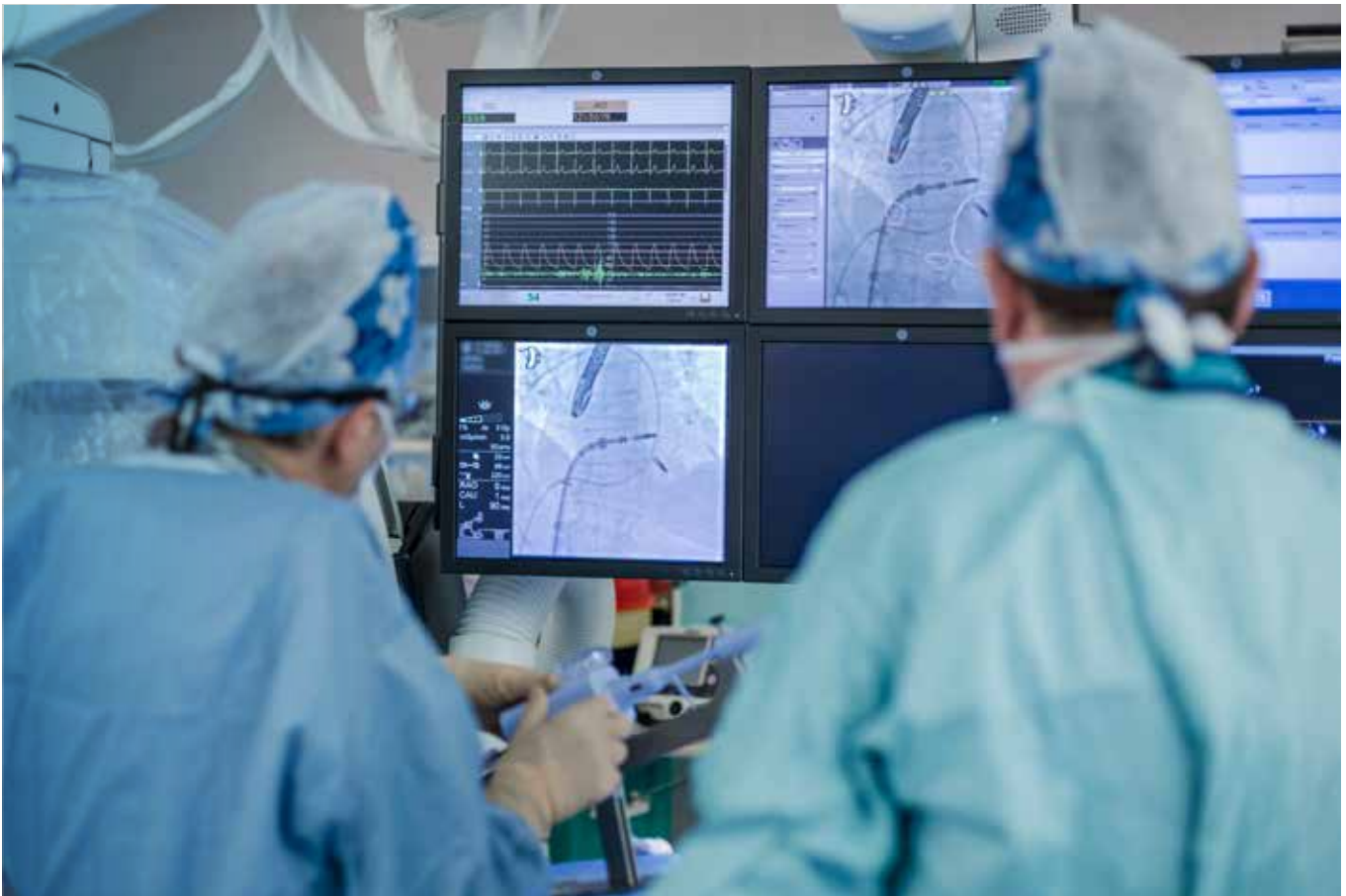

Image fusion with Valve ASSIST 2 during Mitral Valve Repair

Interventional cardiology has undergone considerable developments over the last decade, with image fusion now making it possible to overcome one of the greatest constraints faced by practitioners: the ability to get clear visibility in the operative field. “The introduction of image fusion in the cathlab has changed the way we approach our practice and has led us to develop and perform procedures that are more technical,” confirms Professor Patrice Guérin, Head of the Hemodynamic and Vascular Centre of the Hospital University of Nantes. What are the benefits of image fusion?

“There are numerous examples, the first being the ability to screen a cardiac volume – only virtually, yet extremely close to reality – without emitting any X-ray radiation. Everything is there for us to successfully and safely position ourselves when performing a TAVI or when navigating through the aorta to reach the annulus of the valve.”

Fusion Owns the Future

This is willingly acknowledged by Patrice Guérin: “For us, at the University Hospital of Nantes, many procedures have become inseparable

from image fusion. Particularly congenital heart diseases, which are always unique, with sometimes problematic angulations. Image fusion thus ensures clear visualization and effective guidance.”

The Nantes Hospital also utilizes image fusion to perform the majority of procedures on patients who have already developed heart diseases. In addition to helping to simplify the procedure, it can help reduce the duration of procedures, reduce the amount of radiation delivered, and optimize the amount of contrast required. “In recent years, there has

been a clear recognition of the importance of radiation control. Technical progress now makes it possible to minimize the dose of administered X-rays, by reusing images obtained from previous exams”, states Karine Warin Fresse, radiologist at the Cardiovascular Diagnostic Radiology Department of the Nantes University Hospital. This is a logic that applies to all percutaneous procedures. Even for procedures such as mitral valve treatment – where practitioners are only accustomed to using ultrasound as a guide – image fusion can reduce the duration of the procedure and X-ray exposure, for both patients and healthcare practitioners alike.

The benefits associated with image fusion have led to its widespread adoption by many interventional cardiologists, who rely on its abilities to develop or perfect procedures, such as left atrial appendage closure.

An Additional Benefit for Atrial Closure

The source of a stroke may be traced to the left atrium: blood can stagnate in the heart and coagulate, which may lead the thrombi to collapse. People at risk are usually prescribed blood thinners, but if contraindicated, Left Atrial Appendage Closure (LAAC) is recommended. “Image fusion helps us understand the shape of the appendage beforehand, making sure nothing will be objectionable during the actual appendage procedure. Similarly, the use of augmented reality with Valve ASSIST 2 greatly facilitates the guidance and threading of the device used to close the auricle,” explains Professor Guérin.

Does this mean that the future of stroke prevention lies in the occlusion of the left atrium, using ultrasound and image fusion? The University Hospital of Nantes is convinced that this is the case and has just launched a study whose conclusions may provide better insight into where this innovative imaging technique stands today. “A similar study, conducted on the relevance of image fusion for coronary angiograms (coronography)

of coronary artery bypass surgery, has clearly demonstrated the value of this technique. It suggests that the use of image fusion results in less patient radiation exposure, far lower quantities of iodinated contrast agent injected to the patient, and a very significant reduction in the duration of the procedure,” he confides. This work, carried out by Dr Julien Plessis from the interventional cardiology team of the University Hospital of Nantes, was

The Basics of Image Fusion

“Image fusion is a valuable tool in radiology, providing a visual rendering that was unthinkable less than a decade ago,” recalls Dr Karine Warin Fresse. “Image fusion requires a mastery of tools and effective training for both radiologists and the rest of the team, radiographers in particular.”

Nathalie Musseau, radiographer at the Hemodynamic and Vascular Centre of the University Hospital of Nantes, confirms and explains her role in relevant procedures: “Our work is structured in three stages. We begin by retrieving a CT from a previous exam. This type of image is generally available in over 80% of cases and allows us to avoid exposing the patient to radiation once again.” Second step: Thanks to GE Healthcare’s Valve ASSIST 2 advanced application, 3D reconstruction helps to focus on the volume of interest determined by the physician. “We isolate the volumes of interest that are useful to the procedure by using the volume rendering or contouring techniques that enable relevant threading (trachea, spine, prosthesis, and so on).”

The third stage involves the procedure itself, inside the cathlab and in collaboration with the interventional cardiology team. Radiologists and radiographers ensure that images are continuously registered, delivering optimal effectiveness.

At Nantes, it's About Strength in Unity

“Interventional cardiology at the University Hospital of Nantes in Nantes is about team effort above all!” These are Dr. Karin Warin Fresse’s words to sum up the philosophy of the service. Cardiologists, radiologists and radiographers alike – the whole team strives together to manage as many pathologies as possible non-invasively. “Being an interventional cardiologist doesn’t make sense without an image to handle and without a radiologist to work with. Conversely, the radiologist’s role is only relevant when in collaboration with the cardiologist. And neither of them would go very far without the involvement of radiographers,” adds Patrice Guérin.

Creating this dynamic within the units empowers the entire staff and strengthens the institution. “During a procedure, the radiographer is coupled with the nurse to ensure that the procedure runs smoothly. If the latter is not complex, the radiologist does not even have to be present in theatre,” specifies Nathalie Musseau. As such, operators at the Nantes Centre undergo image fusion training at the GE Healthcare site in Buc (France). The manufacturer is committed to support the medical staff, with the aim to further develop interventional radiology practices.

After being introduced to image fusion in the GE Healthcare premises, operators gradually immerse themselves in the Nantes Hospital with consistent support.

“Radiologists cannot be present everywhere. By delegating some of our missions to operators, we improve the offer and broaden the patient’s host of possibilities,” concludes Karine Warin Fresse.

recently the topic of a publication¹.

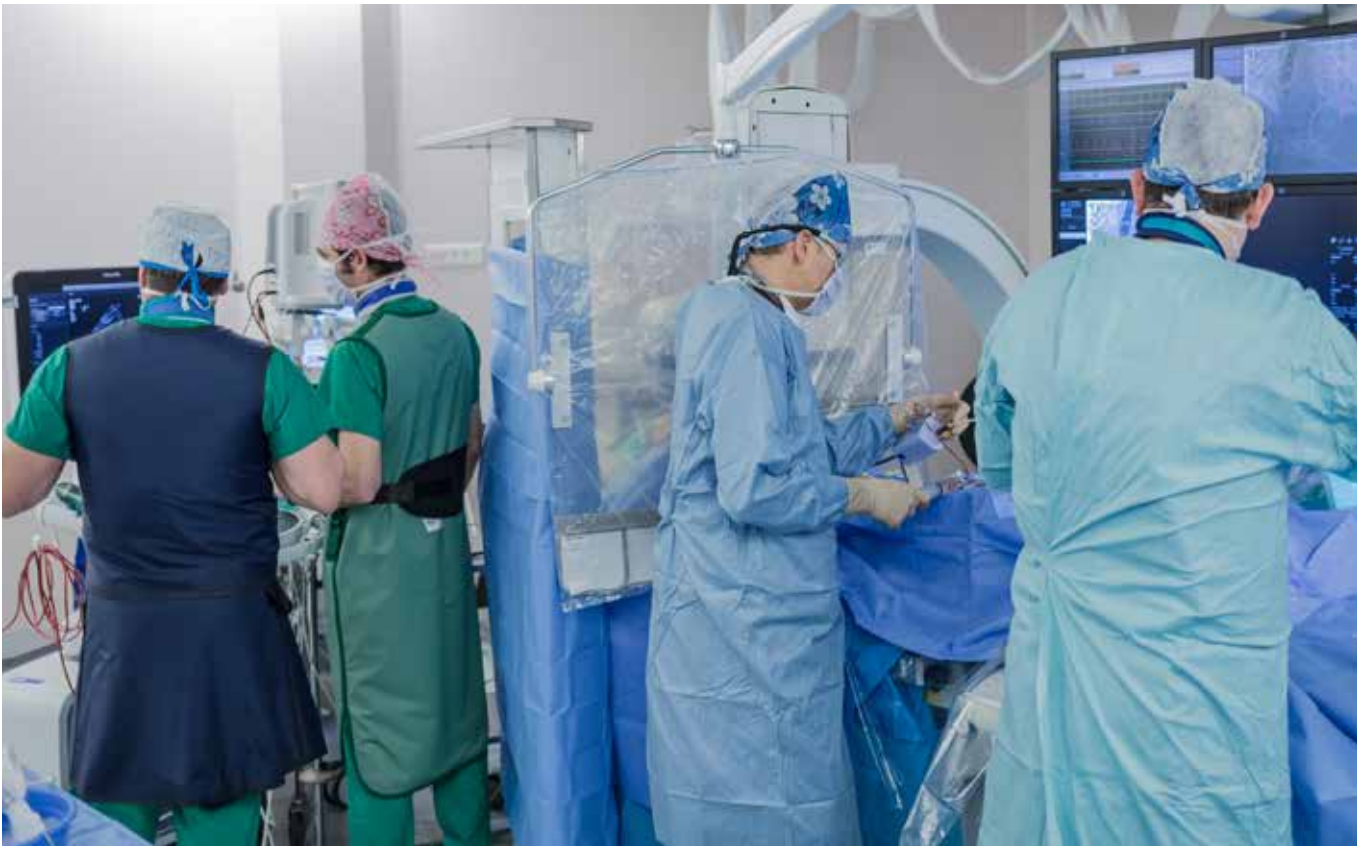A recent study from another team showed drastic benefits of using Valve ASSIST 2 in the planning and guidance of LAAC procedures. In this study, it was proven that the use of Valve ASSIST 2 helped reduce procedure time by 28%, fluoroscopy time by 25% and contrast media by 78% during LAAC².

Tomorrow, a Time for Interventional Cardiology

Image fusion also facilitates Mitral Valve Repairs. This technique consists of treating mitral valve regurgitation with the implantation of a MitraClip (Abbott Vascular, Venlo, CA, USA), without the need to open the patient’s thorax for open-heart surgery. “The principle is to glide through the femoral vein, up to the top right atrium, then reach the left atrium by transeptal puncture. High-definition 3D visualization allows the team to clearly and precisely see the areas of interest. It continues to revolve around the heart during the procedure, in order to locate the inter-auricular septum, then positions itself to face the mitral ring in order to better guide the clip,” details Karine Warin Fresse. She further states that “image fusion is not intended to replace ultrasound or fluoroscopy. It complements the array of possibilities and improves structural cardiology.” In other words, it’s about supporting therapeutic innovation. This potential reminds us of the flexibility needed from such tools and software. The Nantes University Hospital’s hybrid room particularly owes its effectiveness to its Advantage Workstation (AW) at GE

1 Value of Image Fusion in Coronary Angiography for the Detection of Coronary Artery Bypass Grafts, J Am Heart Assoc. 2016 Jun 10

2 Catheterization and Cardiovascular Interventions (2017) :Novel Integrated 3D Multidetector Computed Tomography and Fluoroscopy Fusion for Left Atrial Appendage Occlusion Procedures



Structural heart procedures: a multidisciplinary work involving several modalities

Healthcare. What are its strengths? "In addition to being intuitive and easy to use, the AW (GE Healthcare, Waukesha) can manage images from all types of devices, regardless of the

manufacturer. Based on my experience, I can only reinforce how critical this is and how much this helps us on a daily basis," assures Dr. Karine Warin Fresse.

beneficial for in-theatre medical imaging.

One thing is certain: the future of interventional cardiology – and, by extension, cardiology – relies on the innovative solutions that are and will be developed by the sector's industrial actors. □



Patrice Guérin, MD, PhD, Nantes University Hospital

At a time when image fusion is already revolutionizing daily practices, one radiologist is already thinking of his future, with a clear dream in mind: "Tomorrow, perhaps we'll be able to obtain a 3D image in the form of a hologram, with a heart beating live on the screen. Manufacturers are developing high-speed V technologies. The 3D printing option is already functional on the AW and is especially useful from an educational perspective. But using image fusion in an open space will be even more



How Valve ASSIST 2 helps improve my outcomes for TAVI

Interview with Anna Sonia Petronio,
Head of Cardiac Catheterization
Laboratory, University of Pisa

Please introduce yourself and your facility

My name is Sonia Petronio and I am the Head of the Cathlab Service at the University of Pisa in Italy. At this facility, we have been performing interventional cardiology procedures for many years. We have performed TAVI procedures since 2007 and Mitral procedures since 2008.

The majority of our activity is focused on coronary procedures (60% are ACS patients), and to a lesser extent on peripheral disease and structural heart procedures for adults. We perform approximately 100 TAVI procedures annually and a growing number of MVR procedures, with approximately 30 MVR (mitraclip as well as cardioband) per year. We also are involved in pre CE marked clinical trials for mitral & tricuspid devices.

What are the main challenges that you have faced with structural heart procedures?

The prevalence of challenges associated with structural heart

procedures has decreased over the past few years, with less Major Adverse Cardiac Events (MACE). To limit such risks, we have focused on reducing paravalvular leaks, positioning valves precisely, and avoiding complications.

Ten years ago, a TAVI procedure could take couple of hours to carry out. Since the introduction of new technologies, and once we overcame the learning curve, the time needed for such procedures was reduced. The accuracy of patient screening and valve choice was also improved with the increased accuracy of the measurements.

What are your requirements for pre-op CT to enable effective procedure planning?

We have used CT for TAVI since the beginning and did not solely rely on ultrasound. We also recognized the need to have well trained radiologists. We ask radiologists to utilize good gating for the valve and to obtain clear images of the access route. We are the ones who decide on the device implantation.

We today use the different devices available on the European market.

Please explain your patient triage and workflow for TAVI procedures

In the past, the patient would undergo a CT exam during his or her stay at this hospital. The case would be subsequently discussed within the cardiology team.

When patients do not have a history of coronary disease or angina, we do not keep them at the hospital. We do a CT exam to look at the valve and the coronary. If there isn't any doubt about the health of the coronary arteries, the cardiology team screens the patient.

If there is a doubt about patient's coronary or medical history, the cardiology team screens the patient. Then, we do a coronary angiogram and then we subsequently perform a TAVI procedure.

We then obtain the assessment from the radiologist and measure everything again, which is made easier by the fact that our cathlab is

connected to the radiology department.

Most patients are selected from a list. We know exactly which valve to use, since we choose it beforehand. On the day of the procedure, we have a screening sheet. We use the CT images prior to the procedure and decide on the best angulation to release the TAVI using Valve ASSIST 2. We register the aorta model from the CT on the fluoroscopy by aligning the pig tail catheter on the non-coronary cusp of the model. This fusion allows us to use less contrast during the intervention.

Please tell us more about the key steps involved in the procedure.

We rely on the fusion of the CT image on the fluoroscopy image to do the femoral puncture. Since we have the model of the artery displayed on the fluoroscopy, we don't need to inject contrast to check the artery, as we did

previously for the valve deployment.

Calcification enhancement feature is useful. Sometimes calcium is not well seen and its enhancement allows to understand effect on the prosthesis and the annulus.

As a leader of the database and registry committee at EAPCI, you recently published the European TAVI survey¹. Can you please highlight the main findings?

The survey delivered important information about TAVI procedures and confirmed that what centers (300 centers in 24 countries throughout Europe) are currently doing in is inconsistent with the guidelines. Centers are moving to intermediate and low risk patients; however, they do follow screening recommendations. It also highlighted the need to address the reimbursement problem that was identified both for TAVI and for Mitral

procedures.

Please tell us about the survey on Mitral European centers that will be published shortly.

TAVI procedures, which were for high risk patients, initially generated more adverse events, but when the technique evolved, the procedure proved to be safe and effective for different cohorts of patients. Mitral valve procedures have not improved at the same pace as TAVI procedures, potentially because the pathologies and technologies for the mitral valve are more complex than for the aortic one. □

1. Current status of transcatheter valve therapy in Europe: results from an EAPCI survey, Petronio et Al, EuroIntervention 2016

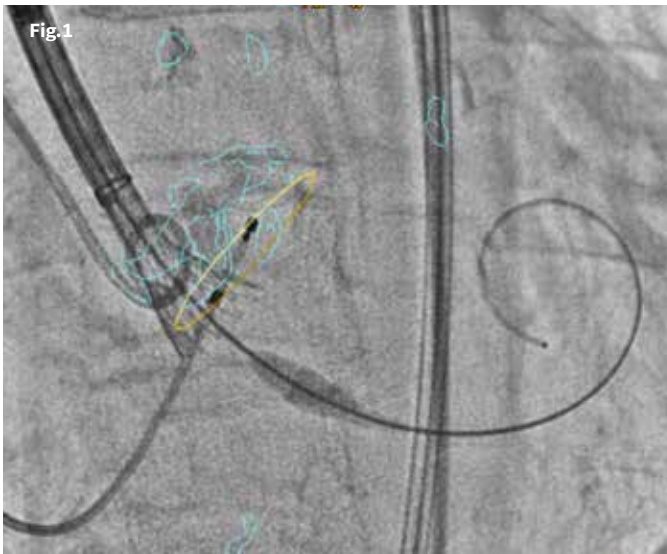


Fig.1 Calcification enhancement view fused with annulus plane and calcifications coming from the planning phase of Valve ASSIST 2, at the beginning of the release of the valve

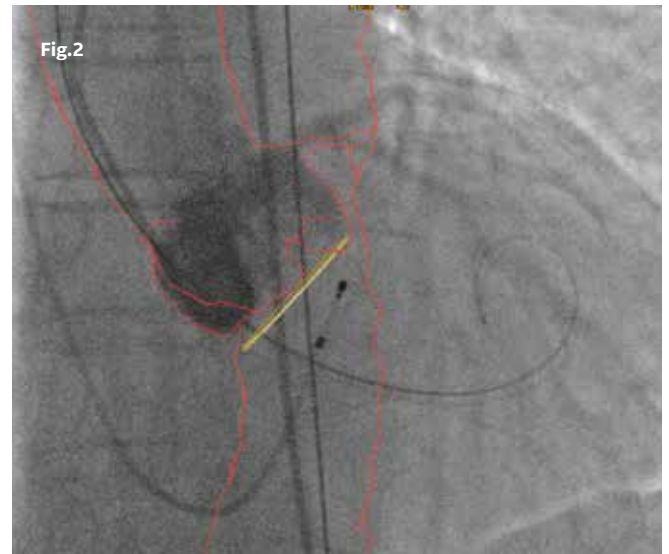


Fig.2 Fusion of pre-op CT with Valve ASSIST 2, gantry position perpendicular to the annulus plane

Find more on GE Cares



Contact

Erika Saillant
erika.saillant@ge.com

A Use of an Inverted TAP Technique for a Left Coronary Lesion

Courtesy of Dr Benamer, Hôpital La Roseraie (Aubervilliers, France)

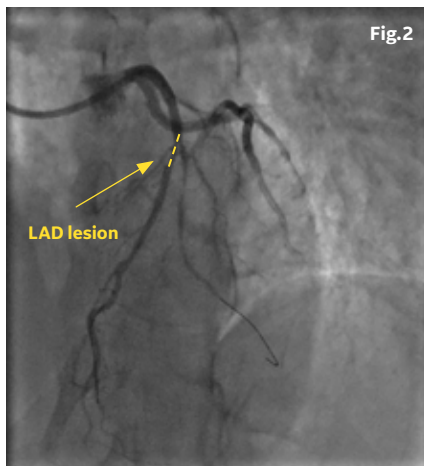
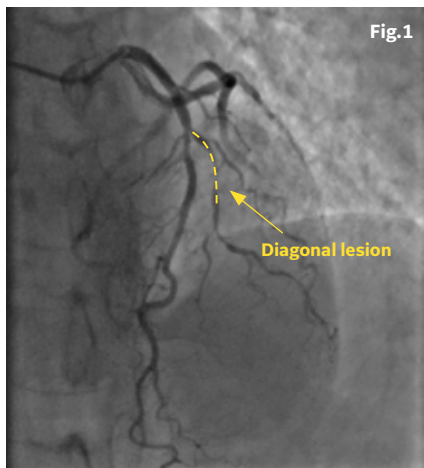


Fig.1 Observation of the diagonal narrowing (FOV 17cm² - LAO: 11° - CRA: 35°)

Fig.2 Observation of the LAD lesion (FOV 17cm² - LAO: 9° - CRA: 33°)

Clinical Challenge

PCI procedures for a stenosis near a bifurcation can require specific stenting techniques. Furthermore, procedure becomes more difficult when the bifurcation has a narrow angle, increasing the pathological risk. Hence, physicians need to be very precise as the positioning of the stent should be exact to avoid post-procedure complications.

Solution

The procedure was performed with the Innova IGS 520 system and the PCI ASSIST package. PCI ASSIST helps improve visibility in moving anatomy and improves visibility in larger patients at the same dose^{1,2}. StentViz enhances stent visibility and visualization to assess stent deployment. StentVesselViz provides a better visualization of the stent in relation to the vessel wall in a fade-in fade-out sequence. StentViz and StentVesselViz helps position the stent precisely and assess its deployment. It is also equipped with InnovaSense, an automatic contouring mode which helps reduce the distance between the receptor and the patient, contributes to optimize imaging geometry, and helps reduce radiation exposure.

Clinical case

Patient History

A 52-year-old woman with a BMI of 23.4 (1m60 for 60kg) suffered from acute coronary syndrome without large ST segment elevation (ACS ST-). Four days prior to the procedure, she had normal troponin.

Procedure

Pathology description

The patient developed two lesions:

- A stenosis in the LAD (distal to the diagonal bifurcation) (Fig.2)
- A narrowed stenosis in the diagonal branch (Fig.1)

In this case, an inverted TAP method was first used to treat the diagonal (side branch). This decision was induced because of the potential threat on the diagonal branch. Indeed, a simple TAP was risky as the future access of the diagonal branch could have been compromised (due to its pathological aspect).

Plan

The patient was lying on her back with her arms along her body. The interventional cardiologist and his assistant were to the right of the patient next to the radial access. They visualized the procedure on the large display monitor in front of them, across

1 Improvement vs. same test without HCF option. IQ & visibility improvement is measured on Innova IGS530 with phantoms using various Plexiglas Thicknesses, acquisition parameters and the NEMA spoke wheel tool (ref 1), calculating the ratio of the contrast of the moving wires to the background noise level. The amount of IQ improvement related to HCF depends on the acquisition parameters, clinical task, patient size, amount of motion in the image, anatomical location, and clinical practice. Ref1: A new tool for benchmarking cardiovascular fluoroscopes; S. Balter, Radiation Protection Dosimetry, Vol. 94, No. 1-2 pp. 161-166 (2001)

23)

2 Results from a multicentric image review based on 11 complex PCI clinical cases

The Inverted TAP

As for a usual TAP (T-stenting And Protrusion), the inverted TAP requires two wires to be positioned in the major branch and in the side branch. Whereas, the usual procedure begins with a stenting in the major branch followed by the side branch, the inverted TAP will first deploy a stent in the side branch with minimal protrusion in the major branch. Then, another

stent is deployed in the major branch covering the bifurcation.

As shown previously, the blood flow in the diagonal was almost stopped. This branch had to be treated first in order to avoid a complete obstruction. Last, a final kissing is performed to open both stent conveniently at the bifurcation and to form the neo carina.

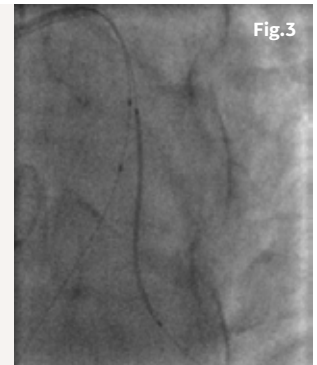


Fig.3 Positioning of the stent in the diagonal and the balloon in the LAD

the table.

The interventional cardiologist decided to perform the procedure by the transradial access which creates less access site bleeding and hematoma risk. The general angulation used during the procedure was LAO 9°, CRA 33°.

Procedure

Once the guidewires were placed in the side branch and the major branch, the cardiologist positioned the first stent in the side branch (diagonal) with a slight protrusion in the major branch (LAD). As this step requires precision, using StentVesselViz helped him to ensure the best possible landing zone. By visualizing the stents markers toward the lesion and the bifurcation (Fig.4), the physician could accordingly position the stent in the diagonal branch (i.e. covering the entire lesion and slightly protruding in the LAD).

After the stent deployment, a post dilatation with a balloon was performed in the LAD to dilate the artery and to ensure that the small protrusion of the first stent wouldn't inhibit the deployment of the second stent in the LAD.

A third stent was implanted distally to the second one to cover a small lesion in the second segment of the LAD.

After the deployment of both stents, a StentViz acquisition (Fig.6) gave two insights to the team. First, the stent in the LAD seemed to be well deployed. Second, as expected, the first stent protrusion is a little bit smashed but a

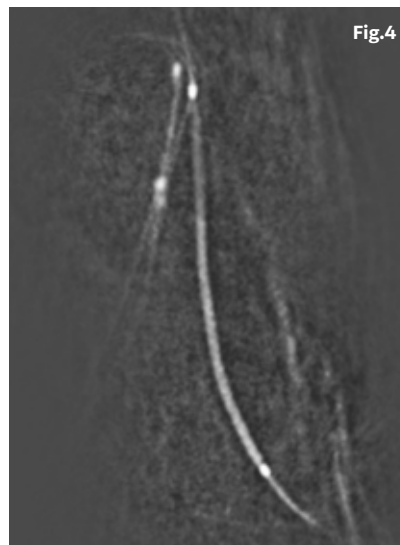

Fig.4 StentVesselViz image used to conveniently position the stent compared to the bifurcation

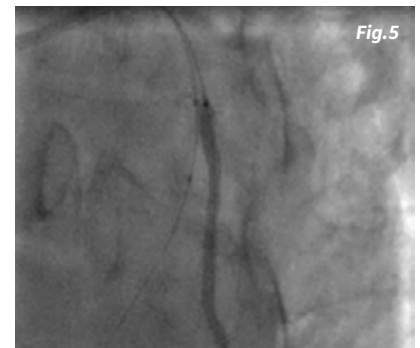


Fig.5 Deployment of the stent in the diagonal

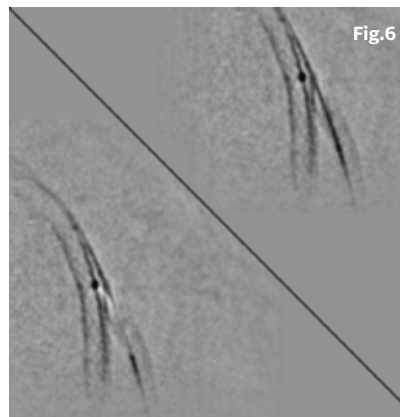


Fig.6 StentViz image showing the smashing of the stent in the diagonal

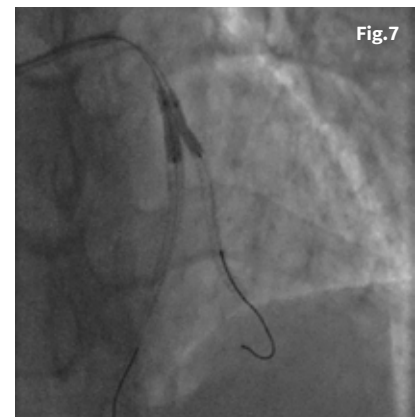


Fig.7 Kissing performed to open both vessels

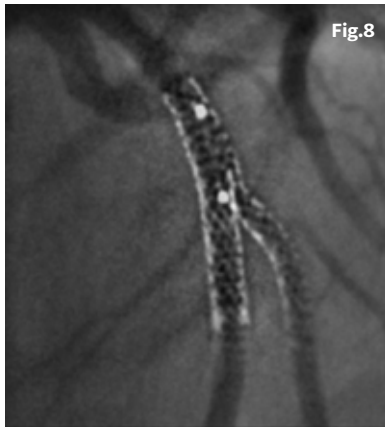


Fig.8 StentVesselViz acquisition enhancing the convenient deployment of both stents and the good opening of the diagonal (Angulation : LAO 9°, CRA 40°)

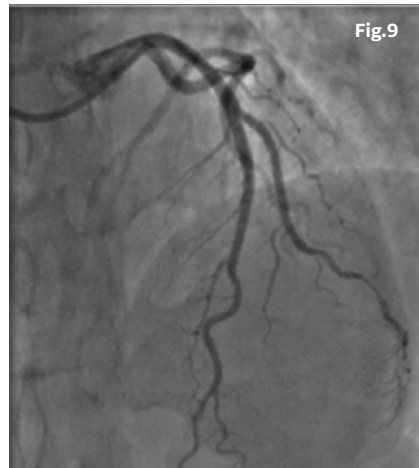


Fig.9 Final assessment of the treated arteries (Angulation: LAO 1°, CRA 33°)

Conclusion

PCI ASSIST^{1,2} improves the image quality in fluoroscopy and record at the same dose with more contrast, less noise and sharper images. StentViz enhances stent visibility and visualization to assess stent deployment. It accurately evaluates stent overlap in cases of in-stent restenosis, long lesions or bifurcation stenting. StentVesselViz provides an excellent visualization of the stent in relation to the vessel wall and thus helps the physician to easily position stents more precisely with respect to existing stents. The PCI ASSIST package increases clinical confidence with immediate and routine control of stent deployment. It can also help physicians reduce the time of the procedure, and minimize dose, without compromising accuracy or the operator's clinical confidence. The entire workflow can be done from tableside and enable substantial dose and time saving during the procedure, while maintaining a good accuracy to increase operator confidence.

kissing will ensure that both the diagonal branch and the LAD are perfectly opened.

Assessment

A final StentVesselViz acquisition (Fig.8) attested that the previous kissing and post-inflation of the LAD were efficient. Finally, the cardiologist completed the procedure with a last acquisition (Fig.9) to control that the result is convenient.

Total DAP (Gy.cm ²)	22.54
Total AK (mGy)	703.06
Fluoro Time (s)	687
Contrast media (ml)	140

About

Dr. Hakim Benamer is an interventional cardiologist at La Roseaie hospital, Aubervilliers, France.
"This technology facilitates complex PCI by improving stent visibility and positioning in bifurcation coronary lesions, particularly when two stents are needed.
It also improves stent deployment, reducing the rate of MACEs in the follow-up.
We are very proud and happy of these applications and we use them in our daily practice very often to enhance our PCI and improve our results."
ICPS (Institut Cardiovasculaire Paris Sud) is a leading French cardiology center, with 11 cardiologists, 2 radiologists and 5 rhythmologists dedicated to treating patients suffering from heart related diseases. ICPS performed 2000+ dilatations, 9000+ exams, 4000+ coronarographies and 1300+ rhythmology procedures in 2013.

Find more on GE Cares



Contact

Erika Saillant
erika.saillant@ge.com



Pushing the boundaries of liver cancer treatment

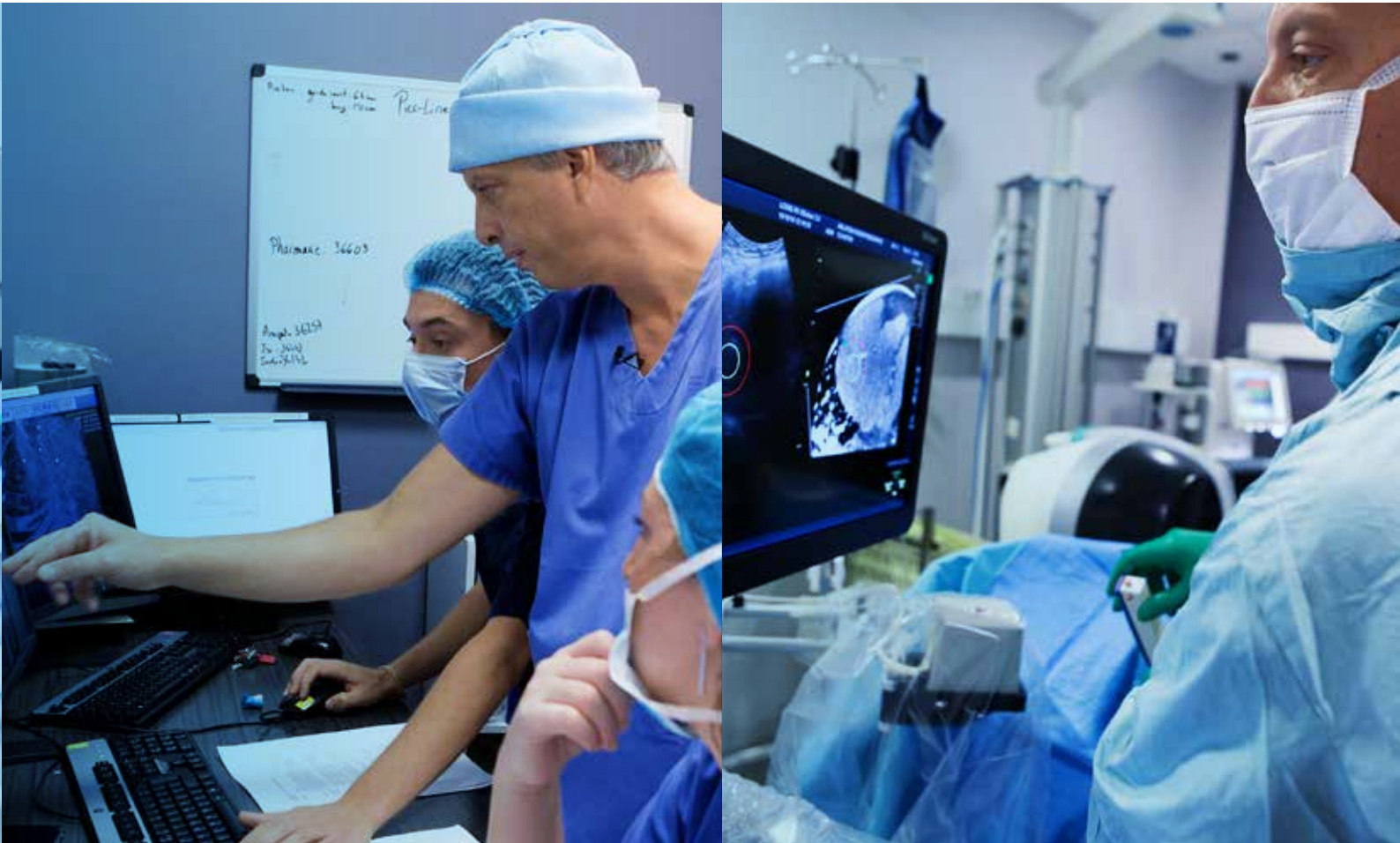Advances in interventional radiology are offering new hope for liver cancer patients, allowing previously untreatable hepatic tumors to be targeted for percutaneous treatment. Professor Olivier Seror is at the forefront of this field and explains how GE Healthcare's Needle ASSIST technology is helping to improve outcomes for patients.



“25% of patients can be transferred to a curative program, just with the use of these new imaging tools”

Hôpital Jean-Verdier in Bondy, Seine-Saint-Denis, is part of Assistance Publique-Hôpitaux de Paris, a network of 39 hospitals providing a full range of secondary and tertiary care services. The hospital is home to a pioneering interventional radiology unit, led by Professor Olivier Seror, which has become an international reference center for the treatment of liver tumors.

There is a range of treatment options available for hepatic tumors, including radiotherapy, systemic chemotherapy, surgery, transarterial therapies and percutaneous ablation, with the latter growing in popularity due to its high efficiency and minimally invasive nature. Ablation techniques have advanced tremendously over the last 20 years – from direct ethanol injection to the use of advanced radiofrequency, microwave, laser and electroporation technologies – but one of the biggest challenges for this approach is still tumor size. Pr Seror explained: “To treat



a liver tumor percutaneously, you must be able to clearly see the target; if you can't see it, you can't hope to destroy it. This means that, for almost a quarter of patients, we can't offer them ablation from a purely technical standpoint. Instead, we have to rely on suboptimal chemoembolization treatments which only have a success rate of around 50 percent, compared to 80 to 90 percent for ablation, so it's a world of difference."

The interventional radiology unit currently performs around 250 percutaneous ablations a year, and

this number is continuously increasing as technological advances make this treatment pathway accessible to more patients. Advances in imaging technologies are at the forefront of this progress, particularly the advent of multi-modality image processing. Pr Seror continued: "No single imaging modality – ultrasound, MRI, CBCT, etc. – can provide all the answers, and so information from these different sources must be merged together. This not only allows the safe and accurate placement of probes and needles, helping to ensure more successful outcomes, but also increases both

patient and staff confidence in these highly complex procedures."

The department is equipped with a state-of-the-art Innova IGS 540 image-guidance system that is allowing more procedures than ever before to be performed within the angio room. Pr Seror commented: "The system's Needle ASSIST feature is particularly useful, providing image fusion and stereotactic needle reconstruction to allow extremely precise placement of needles, electrodes, etc. For example, you can fuse real-time ultrasound imaging with

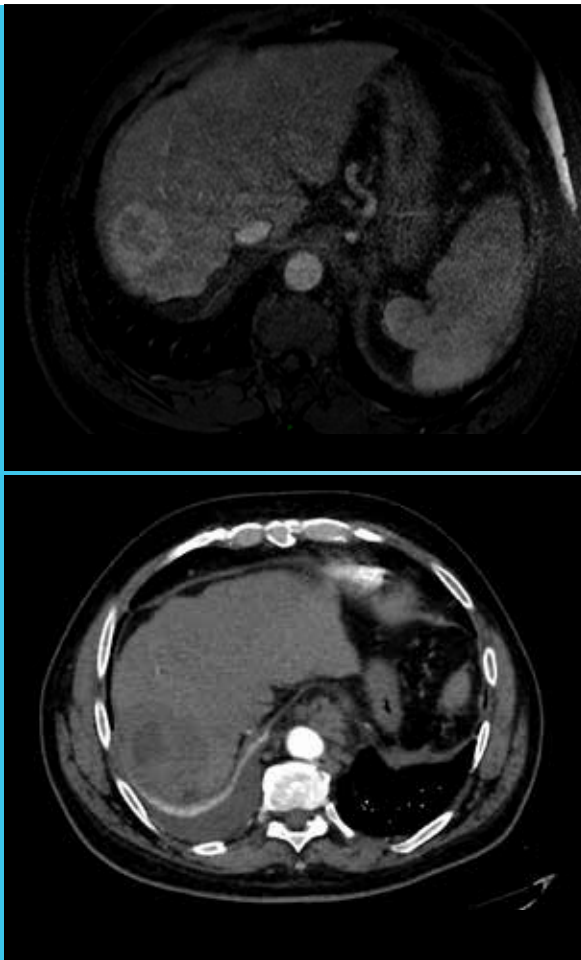
pre-therapy CT and MRI images, without exposing patients to additional radiation doses. This gives us the ability to seamlessly switch from one modality to another, taking advantage of the benefits offered by each and ultimately helping us to achieve our goal of placing electrodes in the right position to obtain the best possible results.”

“The excellent tools we now have available make it possible to perform complex procedures – such as multiple bipolar radiofrequency ablations or electroporation – that we simply couldn’t have attempted just a few

years ago. Most importantly, this technology is allowing us to bring many patients back onto a curative pathway, offering them a long term chance of survival with a low risk of relapse. We estimate that within our hospital around 25 percent of patients who were previously only suitable for palliative treatment can now benefit from ablation – just through introducing these new imaging tools!”

“Hopefully this trend will continue in the future, and further integration of imaging modalities – and even ablation technologies – will help us to push the boundaries of what is

possible. Our partnership with GE Healthcare is an extraordinary asset to help us drive this forward, allowing us to clearly express our needs as therapists and identify new solutions that would help support our clinical practice. As a multi-modal manufacturer producing angiography tables as well as CT, MRI and ultrasound instruments, the company is well placed to develop the next generation of fully integrated imaging solutions,” Olivier concluded. □



Case study

A 65-year-old patient who had received several blood transfusions responded to a Ministry of Health TV advertisement inviting people for hepatitis C screening. Following a positive HCV serology test, ultrasound revealed a 7cm mass in right liver lobe. Despite fact that the patient was being asymptomatic, MRI confirmed the presence of the mass, accompanied by three additional perihilar 3 cm nodules presenting all the characteristics of hepatocellular carcinoma. Someone with a tumor at this stage generally has a surgery, associated with life expectancy of around 12 months.

According to the standard treatment guidelines, this patient would not be suitable for curative treatments. However, the availability of advanced imaging technologies and thermal and non-thermal ablation at Jean-Verdier University Hospital allowed the interventional radiology team to pursue an ambitious program of multibipolar RFA and irreversible electroporation, using 3D fusion techniques, combining CBCT and ultrasound for image guidance. The main tumor and satellite nodules showed complete response with no remission 24 months after the treatment.

Ilio pubic ramus osteosynthesis and cementoplasty

at Gustave Roussy Cancer Campus

Clinical Challenge

Minimally invasive approaches have emerged to treat painful bone tumors, such as thermal ablation (radiofrequency ablation (RFA) or cryotherapy) and consolidation techniques (cementoplasty and osteosynthesis). When performed in the angio room, these techniques are performed percutaneously using CT or fluoroscopy. When performed in the angio room, these procedures often require multiple CBCT to accurately assess the position of the needle in 3D, leading to a substantial increase in patient dose.

Solution

Needle ASSIST helps interventional radiologist achieve accurate and dose-saving needle based interventions. Accuracy is guaranteed all along the workflow as fusion technology allows the user to visualize mis registrations with the help of a dedicated 3D bone rendering, and correct these mis registrations in both translation and rotation in order to achieve accuracy better than 1.8mm on the needle trajectory.

While progressing the needle to the target, Stereo 3D, integrated in Needle ASSIST, allows the user to reconstruct the needle, with only 2 fluoroscopic acquisitions, to help the radiologist localize the needle within the 3D anatomy.

Clinical Case

Patient History

A 70-year-old woman with a history of breast cancer with bone evolution. The patient was suffering from pubic pain due to a fracture in her left ilio pubic ramus. She was referred for cementoplasty and screw fixation in order to consolidate the pubic ramus and relieve pain. The patient's BMI was 35.

Procedure

Plan

The patient was placed in a prone position under general anesthesia. A cone beam CT acquisition of the pelvic anatomy was performed at 40 degrees per second. A dedicated protocol on the Advantage Workstation help to plan the needle trajectory enabling a path to be planned between the patient's skin and the left pubic ramus (Fig.1). The planned trajectory was then superimposed over the live fluoroscopy.

Guide

The off-centered anatomy and high BMI patient prevented the access to a radiological "bull's eye view" angulation. Therefore, needle progression was performed with various gantry angulations including progress view (Fig.2). The 3D model was registered (both in translation and rotation) over the live fluoroscopy to ensure accuracy.

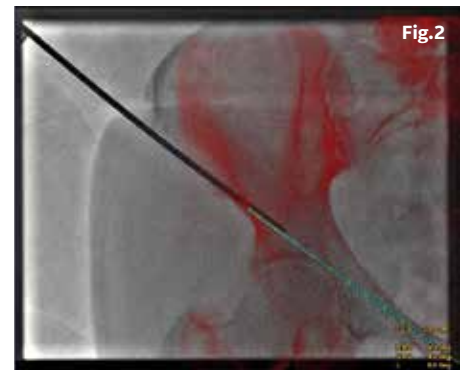
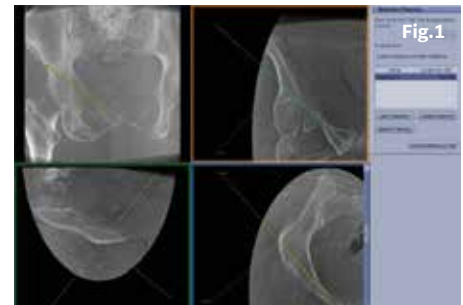


Fig.1 Trajectory planning

Fig.2 Progress view

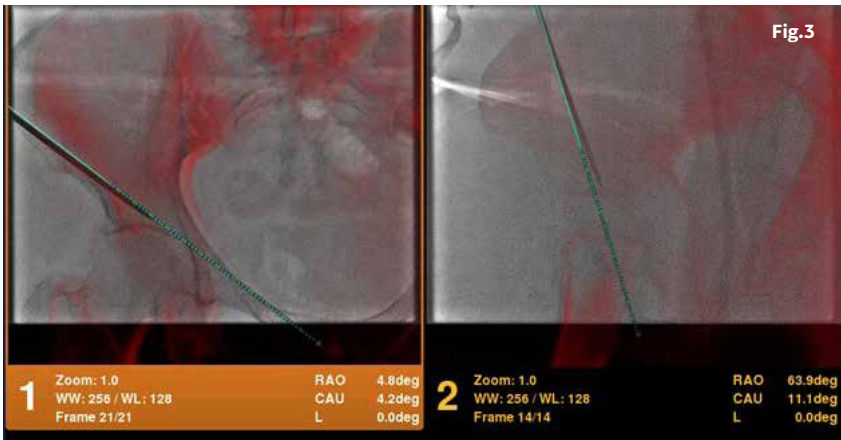

Fig.3

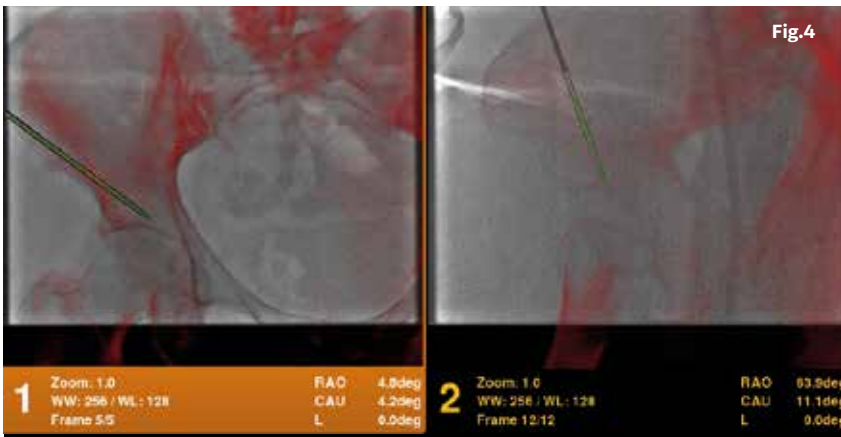


Fig.4

Fig.3 Fluoroscopic view used for the needle reconstruction using Stereo3D

Fig.4 Needle detection after registration finetuning

After inserting the needle a few centimeters into the bone, the clinician wanted to ensure that the needle was following the targeted trajectory. Stereo3D was used to reconstruct needles from two spatially separated fluoroscopic images to help localize the needle in the 3D anatomy (Fig. 3). Optimal angulation was automatically computed for each shot, and reached by the gantry using autopositionner. Once the two fluoroscopic images were acquired, the registration between the anatomy based on bone rendering and fluoroscopy was checked side-by-side. The needle was then detected on both views and automatically reconstructed. The needle was then exported to Volume Viewer and displayed on the MPR cross section of the previously acquired CBCT to assess its relationship with the anatomy (Fig.5).

Assess

The precise location of the needle was assessed on oblique views and compared to the initial planned trajectory. A "projective" distance was given to the physician, showing him the remaining distance to reach the target. This distance is represented in the image by the dotted bold line.

Based on this result, the physician decided to reposition the needle in order to reach the target in the pelvic bone. A second Stereo3D was done after repositioning the needle to check that the correct path was reached this time (Fig.6).

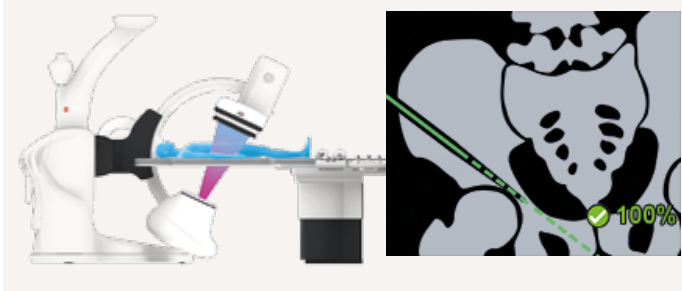
Once the screw insertion was finished, a 11G Cook cimentoplasty needle (Bloomington, IN, US) was placed

Stereo3D Workflow

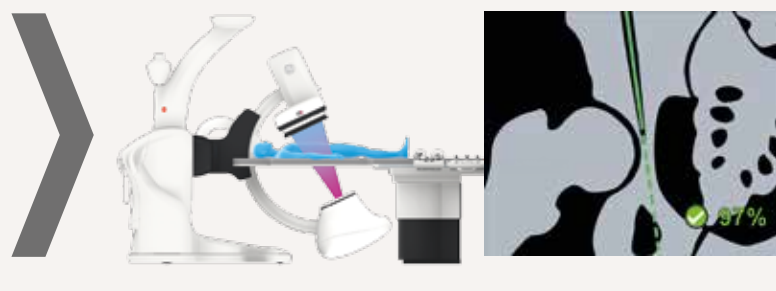
- 1 Launch Stereo3D workflow

START

- 2 First fluoroscopic shot and computation of second angulation



- 3 Second angulation reached thanks to autopositionner and second fluoroscopic shot



coaxially to inject cement to anchor the screw.

Outcome

The post-treatment CBCT acquisition (Fig.7) showed satisfactory screw and cement distribution after injection, with no leakage.

After one month, the VAS (Visual Analog Scale) was at 0/10 versus 7/10 before the procedure.

Conclusion

Needle ASSIST provides live 3D needle guidance during needle based procedures. It guides the physicians as they advance the needle down a planned trajectory overlaid with live fluoroscopy, which allows them to visualize any deviations from the desired path.

The Trajectory Planning protocol helps plan needle trajectories by selecting the entry and target points. Stereo3D enables the physician to reconstruct the position of the needles in the 3D anatomy from two fluoroscopic acquisitions, without doing a CBCT.

The entire workflow can be done from tableside, reduce the time of the procedure, and minimize dose, without compromising accuracy or the operator's clinical confidence.

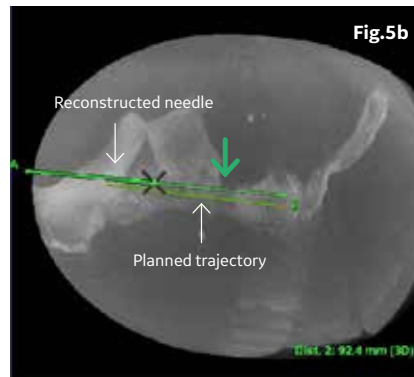
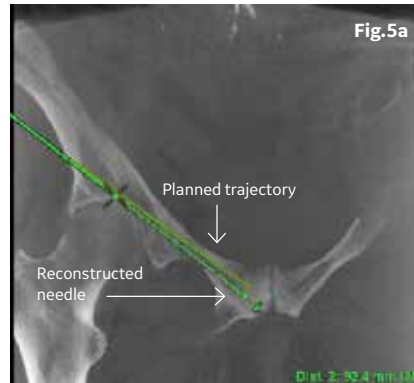


Fig.5 Needle reconstructed and displayed on the preoperative CBCT (bold line green) and initial trajectory (thin line green). → Risk of bone effraction

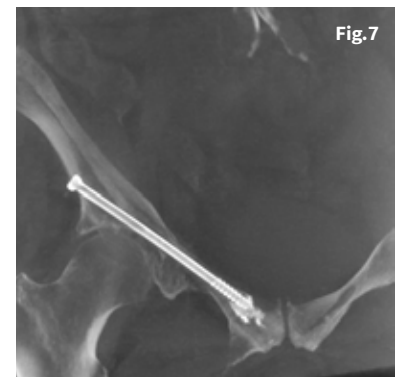
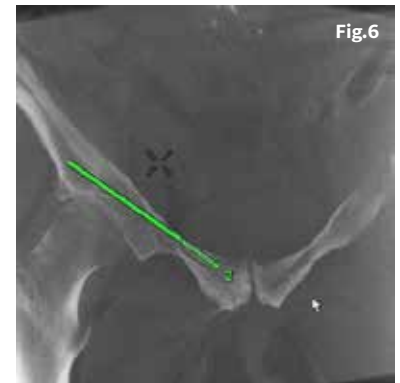

Fig.6 Needle reconstructed after trajectory modification (thick line corresponding to the needle position, while dotted line representing the remaining path to the target)


Fig.7 Final CBCT

About


Dr. Lambros Tselikas is an interventional radiologist at the Gustave Roussy Cancer Campus, Villejuif, France. He says that Needle ASSIST increases his confidence to perform needle-based interventions in the angio room and simplifies his workflow by helping him avoid multiple CBCT acquisitions.

The Gustave Roussy Cancer Campus, a leading European cancer center, brings together 2500 men and women dedicated to treating patients suffering from cancer, conducting research, developing new therapies, and passing on knowledge to the medical and scientific communities in France and worldwide. The interventional radiology unit performs approximately 3500 oncology procedures per year (RFA, TACE, biopsies, cementoplasties, and others).

4 Validation of registration and automatic needle detection



5 Automatic needle reconstruction and display on the CBCT

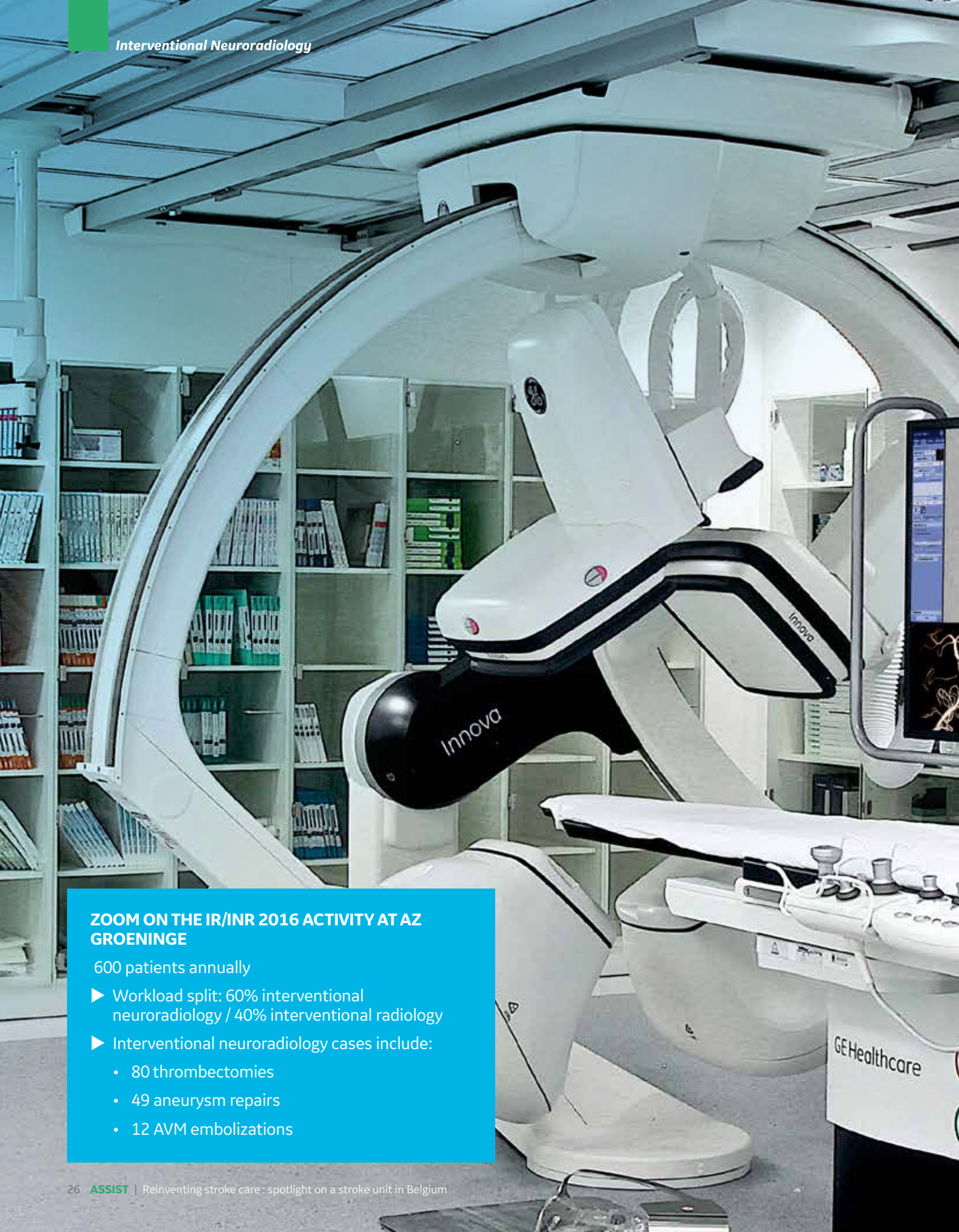

Find more on GE Cares



Contact

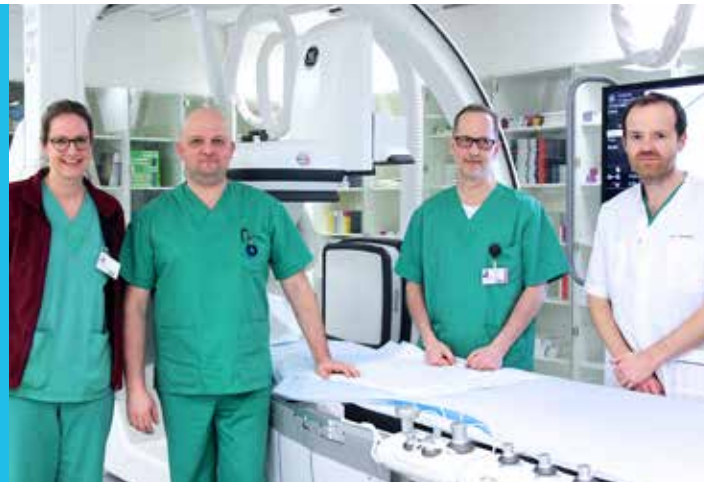Dustin Boutboul
dustin.boutboul@ge.com



ZOOM ON THE IR/INR 2016 ACTIVITY AT AZ GROENINGE

600 patients annually

- ▶ Workload split: 60% interventional neuroradiology / 40% interventional radiology
- ▶ Interventional neuroradiology cases include:
 - 80 thrombectomies
 - 49 aneurysm repairs
 - 12 AVM embolizations



Reinventing stroke care : spotlight on a stroke unit in Belgium

MR CLEAN, ESCAPE, SWIFT PRIME, REVASCAT... The publication of these randomized clinical trials in 2015 demonstrated the benefits of using mechanical thrombectomy, creating a tsunami in the realm of stroke management. Since then, interventional neuroradiology departments have sought to adapt to the flow of incoming stroke patients. This shift has changed the lives of stroke management teams, who have been confronted with emergency procedures in the middle of the night and changing guidelines and reimbursement policies for stroke management. The interventional radiology department at the AZ Groeninge hospital in Kortrijk, Belgium opened end of 2014, at the dawn of the tsunami.



The stroke care network in Belgium

Dr. Olivier François is an interventional radiologist who specialized in interventional neuroradiology in 2002 and worked in Antwerp and Aalst, before being hired to create the department at AZG. In the following article, he tells us all about the network of stroke care in Belgium and how AZG organized the interventional neuroradiology unit almost three years ago when confronted by the sudden increase of stroke patients.

Can you explain how the network of stroke care is organized in Belgium?

"Following the publication of thrombectomy trials in 2015, the Belgian government announced that regional stroke care units would be established. It stated that so-called S1 centers will be primary stroke centers and handle first line diagnosis of stroke patients and IV thrombolysis administration, and S2 centers will be comprehensive stroke centers certified to perform endovascular procedures (thrombectomy) for stroke treatment. However, the Belgian government has yet to define which hospitals will be S1 and S2 centers.

There are approximately 20-25.000 stroke patients in Belgium every year, so one can expect that about 12 to 15 comprehensive stroke centers will be certified. Criteria to become an S1 or S2 centers are already defined, but geographical considerations as well as the cultural separation of the country between Walloon and Flanders make the decision a political one.

So far, there is no reimbursement for thrombectomy in Belgium and the

cost, which varies between 5000€ and 10000€, is supported by the hospitals. It has a big financial impact on Belgium currently."

What is the standard care pathway for a stroke patient at AZG?

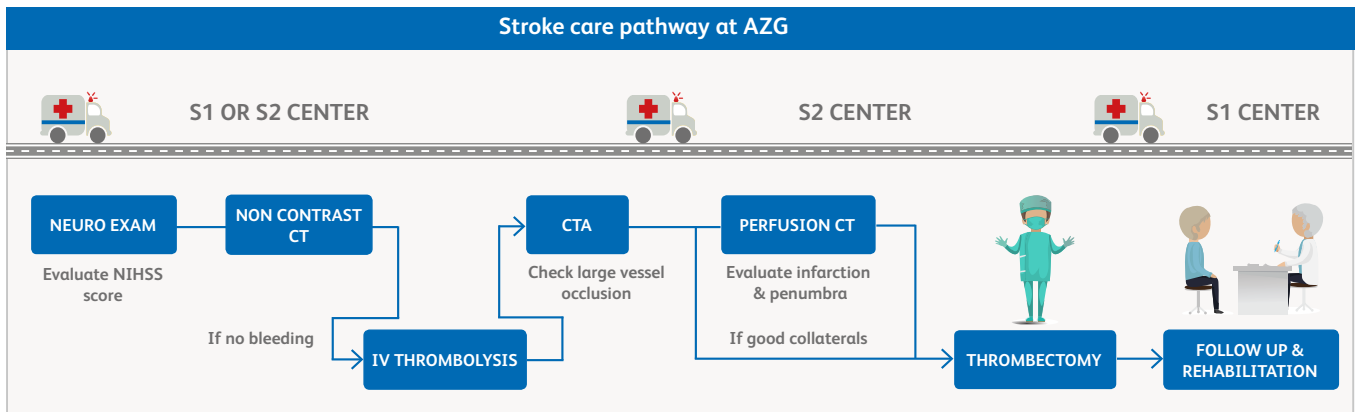
"Patients with symptoms are immediately transferred to the closest center for diagnosis or directly to AZG. A non-contrast CT is performed in order to rule out a brain hemorrhage and confirm the ischemic stroke type. A IV tPA is administered if indicated. Shortly after, a CT angiography (CTA) is performed to evaluate whether the ischemic stroke is proximal (large brain vessel occlusion). Collaterals are also evaluated on the CTA, in order to verify the level of brain perfusion. At this stage, if large brain vessel occlusion is confirmed, the patient needs to be transferred to our center for further evaluation and treatment.

In our case, stroke patients transferred from another center represent 45% of our stroke patients, and they are directly brought to the neurology unit. The ER is skipped, which saves time for the admission. Our on-call stroke team is informed by the ambulance in

"So far, there is no reimbursement for thrombectomy in Belgium and the cost is absorbed by the hospitals"

advance and starts preparing to receive the stroke patient. The neurologist receives the patient and performs a quick neurological exam to re-evaluate the NIHSS (National Institute of Health Stroke Scale) score after thrombolysis. The higher the score, more likely it will be that the patient is sent for a thrombectomy as it is symptomatic of a large vessel occlusion.

Perfusion CT is often performed to further evaluate brain perfusion and the extent of damages and salvageable brain tissue but in some cases, if the team thinks that thrombectomy will be performed anyway, then the CT perfusion step is skipped to save precious time. Typically, about 50% of patients have a large vessel occlusion, and only a third of them will have thrombectomy because the others present too late. This means that 10% to 15% of all ischemic stroke patients admitted who will benefit from a thrombectomy procedure."



Learn from the experts: opening a comprehensive stroke unit

Dr. Olivier François (OF) & Pr. Tommy Anderson (TA) both created the neuroradiology unit from scratch. They share their top tips for improving the efficiency of stroke care.

When was the stroke care unit created and how was this done?

OF: "I was already performing a few thrombectomy cases every year when I worked in Aalst, but the timing of the trials publication corresponded to the opening of our interventional neuroradiology unit in Kortrijk, the number of cases grew right away. We managed to have Pr. Tommy Andersson work here to help us manage our workload and create the stroke unit. Currently, there are approximately ten S1 centers that refer their stroke patients to us for

thrombectomy, both from the Flemish and Walloon regions.

It's crucial to have a real team for stroke care, where everyone is pro thrombectomy. Our stroke team at AZG is composed of three interventional neuroradiologists, seven nurses, neurologists, neurosurgeons and anesthesiologists. Initially, Pr. Andersson and myself provided a lot of training to the nurses on how to act as fast as possible, and they all went to the Karolinska University Hospital for practical training in the neuroradiology department and stroke unit. Training was key."

We often say "time is brain" when talking about stroke care. What did you put in place to increase the speed of your care pathway?

TA: "One of the most important things to put in place to save time is to have pre-defined roles for each member of the team. Everyone has their own responsibilities within the process, so we work in parallel, not one step after

the other. If we decide to do the procedure, everyone knows what they have to do according to a flowchart of tasks that was defined."

OF: "There's a learning curve for all of us, so there has been a marked decrease in the time required compared to the beginning. We are part of the Swedish National Quality registry EVAS, so we register each time index, which helps us to see what we could do better and how to save even more time.

"It's crucial to have a real team for stroke care, where everyone is pro thrombectomy"

Another important point is to limit transfers, to avoid wasting a lot of time. In our case, the emergency team knows they have to skip the ER, and admit the stroke patient immediately to the radiology department, so that the neurologist can perform the neuro exam right away.

As soon as we see there's no bleeding in the brain, we directly do the thrombolysis in the CT room (Discovery HD, GE Healthcare), where there is a kit available for this purpose. And only then, we do the CTA. Finally, in our new hospital, the CT room is one corridor away from the angio room so the patient can be transferred to treatment very quickly."

Did you define key performance indexes for your stroke care unit and how do you measure them?

OF: "Every thirty minutes of delay in revascularization means 10% fewer positive outcomes for stroke patients, so you need to track time. It is mandatory in Belgium to apply as an S2 center. One can find the recommended time stamps in the guidelines and literature. There are typically three main guidelines: door-to-needle time for intravenous therapies and door-to-groin time plus

groin-to-reperfusion time for thrombectomy treatments. Door-to-needle time is the time between arrival at the hospital and thrombolysis. It is very short in our hospital given the shortcuts we have been able to make when a stroke patient arrives. Door-to-groin time is the time between arrival at the hospital and groin puncture in the angio room to start thrombectomy. Right now, it's between 45 and 60 minutes in our case, but our objective is to decrease it to 30 minutes. And then groin-to-reperfusion time is the duration of the thrombectomy procedures from femoral puncture to removal of the clot. We aim another 30 minutes to take the thrombus out, so it would be one hour in total between hospital entrance and reperfusion."

TA: "Currently, 55% of our thrombectomy patients have positive outcomes, based on the modified

Rankin Scale (mRS). This reflects what you find in the literature, but it depends on your selection criteria. The stricter you are in selecting who will receive thrombectomy, the better your outcomes will be. It's a balance between not excluding patients who might benefit from thrombectomy, and not performing if there isn't good chance of recovery. But if you are reasonably strict, you end up at 55% typically."

What type of imaging do you use during your thrombectomy cases?

OF: "Normally, I just use standard 2D images to be fast. Sometimes, if access is difficult, I might create some fluoroscopy roadmaps. I also use my biplane system (Innova IGS 630, GE Healthcare) in monoplane mode for thrombectomy cases, again for the sake of time, but then at the end of the case, when the clot is gone, I do a control in biplane mode. Stroke



patients move all the time, we use conscious sedation and head holders to minimize risks of movements, but it is still essential to try to work as fast as possible.

Radiation dose and contrast reduction are obviously not the main concern for these patients, but I always try to work with very low dose protocols by default since image quality is good enough for thrombectomy. Whereas for more complex cases such as arterio-venous malformations and aneurysms, I adjust image quality and dose to a higher-level protocol."

Do you use tools to detect intracranial hemorrhage in the angio suite?

TA: "Our rate of bleeding is less than 5%, which is the normal range. Bleeding is mostly due to the stroke itself which may cause a rupture of small vessels, rather than the

procedure itself. It typically happens within a day after the procedure, so we perform an MR twenty-four hours after the procedure to check for a bleeding, or a CT exam if MR is contra-indicated. But there is usually iodine leakage through the blood brain barrier from the procedure, which might be confused with blood on plain CT, so dual-energy CT is normally preferred to avoid misinterpretation. With MR, on the other hand, there is often an overestimation of the infarct, and the patient can be better than what you would think.

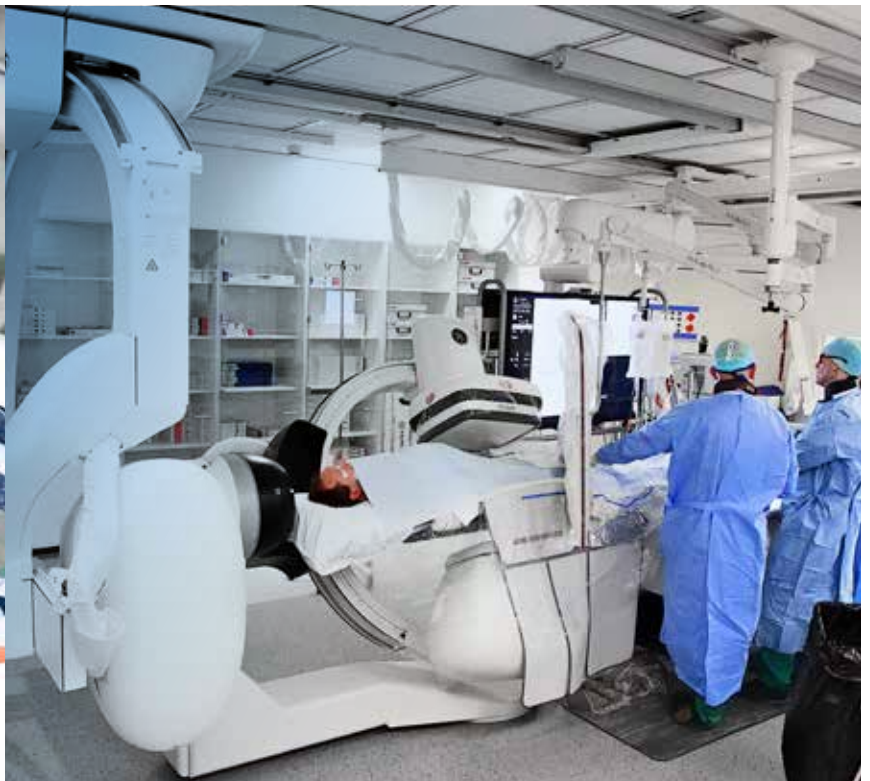Now, we are planning to do a 3D acquisition (Innova CT HD, GE Healthcare) immediately after each case to check for bleeding and to have a baseline to be able to compare with MR images twenty-four hours later."

What made you choose your equipment, the Innova IGS 630?

"The Advantage Workstation is remarkable."

OF: "I first used it before in Aalst, and I was very happy with the collaboration with GE Healthcare. The collaboration and the after service are important considerations when you make such a choice. Also the 3D is of excellent quality, together with the low dose protocols that are available. And lastly, the Advantage Workstation is very easy to use and very intuitive."

TA: "I think the strength of GE systems is truly the workstation. The Advantage Workstation is remarkable. And then also, you need to work with a company that has an interest in helping you, and for which you mean something." □





A look ahead

Prof. Tommy Andersson is an interventional neuroradiologist from Karolinska institute and he spends one week out of three at AZG to reinforce the team and work with Dr. François on neuro cases. He shares his vision of the future of stroke.

Pr. Andersson, where do you think that stroke research is going these days?

TA: "I think pharmacology will strike back at stroke and new drugs will be developed that will be more potent and more efficient at dissolving clots. There's also research on rehabilitation drugs and neuroprotection drugs to protect the brain, especially during the early phases of ischemia. Neuroprotection was a hot topic many years ago, but the side effects were tremendous so research halted at some point. Cooling is an option that works well, but it is difficult to put in place. In the end, quick reperfusion remains the key."

Regarding devices, I think that in the future we might select thrombectomy devices depending on what type of clot is blocking the vessel, and not only depending on the vessel size or a gut feeling. Being able to analyze the composition of clots and adapt to it might be an answer.

In terms of imaging, we need more and quicker imaging in the angio suite. We could skip the CT perfusion, at least when we really suspect that the patient will benefit from thrombectomy. We just need to make sure that there isn't bleeding and then go on with the thrombectomy. Being able to

confidently detect bleeding in the angio suite would be useful. And then I think we need to extend the time window allowed to do thrombectomy. With good collaterals, twelve hours can be ok. So, if we see clear collaterals and we have a young patient, let's skip perfusion and do the thrombectomy."

"If you want to start, you should be mentally prepared and completely dedicated."

Who do you think should be performing thrombectomy in areas where trained neuroradiologists are missing?

TA: "There's a debate about cardiologists handling these cases in some countries, because they have the catheter experience and are used to handling emergency situations. They indeed have part of the training, but not the knowledge of the brain."

Challenges are quite different in Belgium and Sweden, where I come from. One is very dense, with many people who want to do thrombectomies, and the other one is very large with not enough centers and trained neuroradiologists. In Belgium, the law states that the procedure should be done by a

neuroradiologist, but in Sweden, the question remains open to some extent. Some centers want to do it, and it is justified in terms of location, but they don't have the staff.

So there is an ethical question. Is it better not to do it at all, or do it reasonably well? Personally, I don't believe that shortage is an excuse to do things badly."

Which advice would you give to someone who wants to open a comprehensive stroke care unit?

TA: "I would say that the first thing is to make sure you get the knowledge about stroke, about guidelines of what you should do, and then the training and the experience through practical training. You cannot do it just like that, you need these three components."

Then, make sure that you work as a team. You cannot do anything without the whole team (neurologists, nurses, neurosurgeons if there are complications and other interventional neuroradiologists). Being part of a stroke care team is very demanding for the whole group, it is not an 8am to 5pm business. It requires personal investment because you need to be available 24/7. So, if you want to start, you should be mentally prepared and completely dedicated." □

Acute Ischemic Stroke treatment using Innova IGS 630

Courtesy of Dr. O. François, AZ Groeninge Kortrijk (Belgium)

Clinical Challenge

Acute ischemic stroke is one of the leading causes of disability and death. Fast restoration of cerebral blood flow by vessel recanalization is key to improve outcomes and reduce mortality. Every thirty minutes of delay in revascularization means 10% fewer positive outcomes for stroke patients. To be as quick as possible, it is essential that dedicated teams work with specific workflows and specialized equipment

Solution

The procedure was performed with the Innova IGS 630 biplane system. A stent retriever was used to remove the clot under temporary balloon occlusion of the internal carotid artery with an 8F Balloon Guided Catheter.

Clinical case

A 73-year-old woman was at home when she partially lost vision in her left eye and her speech became slurred. Start of her symptoms was indicated at 11:30 AM. She was admitted in the nearest hospital where a CT scan confirmed the suspicion of ischemic stroke. After confirmation, intravenous thrombolysis was performed immediately.

66 minutes after symptom onset, the Stroke Center of AZ Groeninge Kortrijk was contacted to prepare for an

endovascular ischemic stroke treatment.

Non-contrast and contrast-enhanced CT were reviewed on the PACS workstation while the patient was transferred. The stroke-team decided to skip CT perfusion to gain precious time and save more valuable brain tissue.

At 13:19 the patient arrived at the hospital and was transferred immediately to the prepped angiogram room. Her score on the NIH stroke scale was 18, which indicated a severe neurological deficit.

Procedure

The procedure was performed under conscious sedation. At 13:35 the retrograde puncture of the right common femoral artery was done. An 80cm long 8F arrow sheath was used to reach the right common carotid artery after selective catheterization over an 5F catheter.

Angio

DSA-images showed an occlusion of the middle and distal M1 segment of the right middle cerebral artery (MCA). A good collateralization via the right anterior and posterior cerebral artery was confirmed. The patency of the right common carotid, the carotid bifurcation and the cervical segment of the internal carotid artery was good.

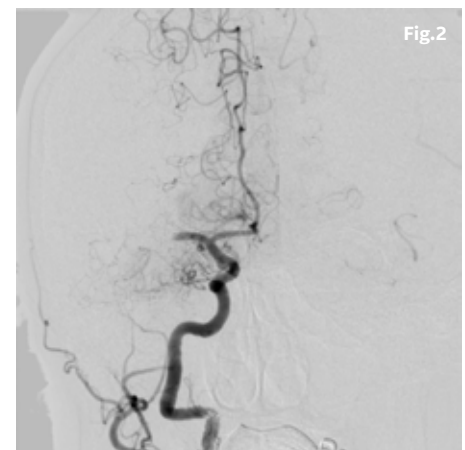
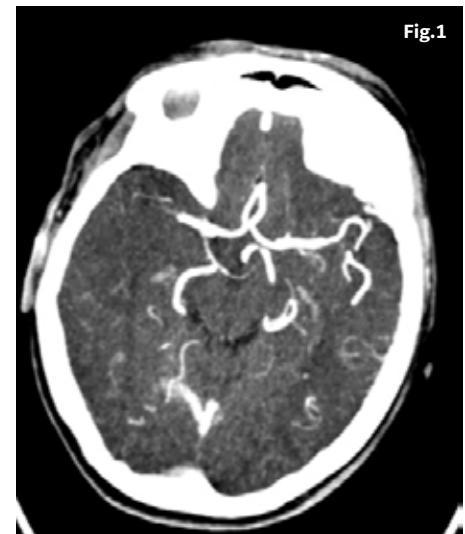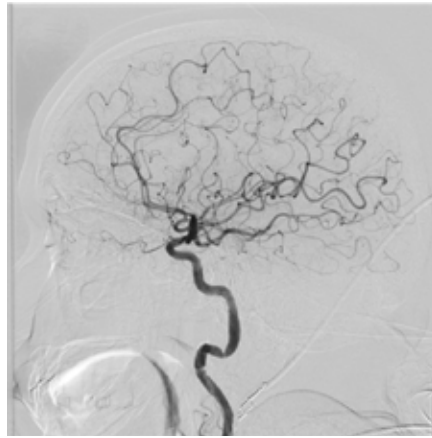
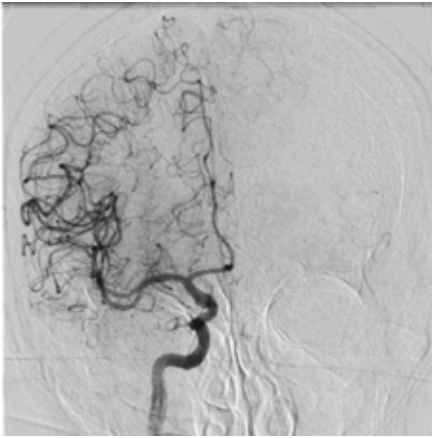
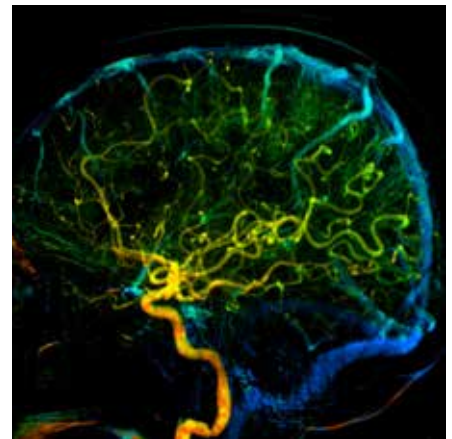
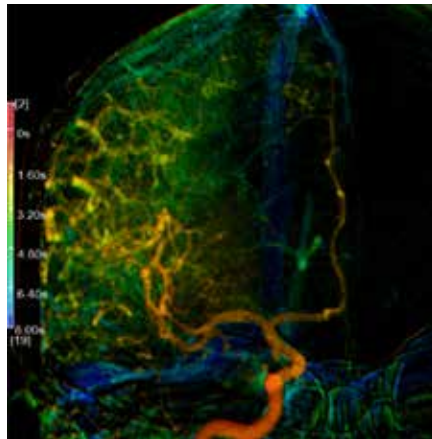
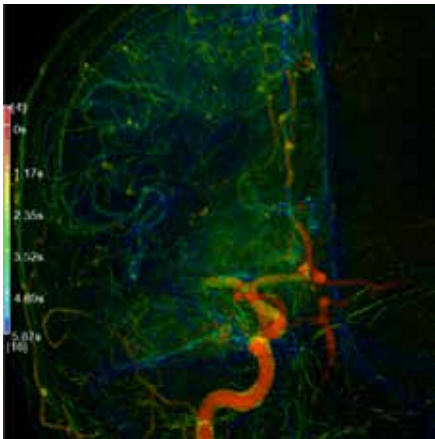


Fig.1 After exclusion of hemorrhagic cause of symptoms. Angio-CT showed occlusion of the mid M1 segment



Mechanical thrombectomy

A stent retriever was placed on the level of the occluded segment. After 5 minutes of incubation, the entire clot was removed under a temporary balloon occlusion of the right internal carotid artery with an 8F balloon guided catheter and manual aspiration. The control angiogram showed a complete restoration of patency of the right MCA.



Angioviz

Visualization of vascular flow characteristics before and after cloth removal with Angioviz, to check collateral circulation and the quality of the brain perfusion.

Total DAP (Gy.cm ²)	14.81
Total AK (mGy)	99
Fluoro Time (s)	8:49
Contrast media (ml)	90
Number of DSA images	129
Door-to-groin time	16 min
Groin-to-reperfusion time	20 min
Door-to-reperfusion time	36 min

Conclusion

The entire stroke care pathway was very quick, with a door-to-needle time of 16 minutes and a groin-to-reperfusion time of 20 minutes. Overall reperfusion was achieved 2h and 25 minutes after symptom onset. A follow-up CT 24 hours after thrombectomy showed no bleeding and confirmed that the patient was in good condition.

Find more on GE Cares



Contact

Victorine Vervaeke
victorine.vervaeke@ge.com



Driving change in the IR department of Marseille's Timone University Hospital

Marseille's Timone University Hospital is developing state-of-the-art medical care. Built to meet the establishment's pursuit of excellence, its new building now hosts 4 interventional radiology labs, including a hybrid room equipped with a Discovery IGS 730. The device's technical capacities and flexibility allow teams to collaborate and deal with ever more complex cases, making it stand as a cutting-edge piece of technology, strengthening both the interventional radiology offer and the initiatives that result from local collaboration.

Bordering Marseille's historic city centre, La Canebière high street and its old port, one will find the Timone Medical University Centre, a hospital of the AP-HM (Public Assistance – Hospitals of Marseille) built in the 70s. Timone is the PACA region's largest health institution. As such, it stands alongside Europe's greatest centers, both for its activity and for its equipment and technology. Its core ethos: to achieve excellence. It is this high expectation that has led management to pursue extensive renovation and expansion efforts

during the 2000s, later embodied by the inauguration of a new medical technology infrastructure in 2013, humbly baptised "Timone 2". Sprouting up from a large-scale worksite, these new premises were designed in close collaboration with the medical staff, gathering expert teams with ultra-modern equipment: emergency ward, resuscitation unit and operating theaters and the medical imaging unit. Beyond bringing together services which were once scattered, Timone 2 draws out a new living and working philosophy: "All

functional units of the adult radiology and neuroradiology services have been gathered in one site to accommodate current and future activity," says Alexis Jacquier. "The gathering and homogenization of teams foster an atmosphere and a sense of unity that is synonymous with great leaps forward, both at the professional and human level. Furthermore, the patient and doctor circuits have been optimized simultaneously. The team's dynamic is only strengthened by this." In rethinking the standard care pathway





“New technologies are allowing us move forward. In 10 years’ time, all surgeons will be applying interventional radiology techniques, as the trend is to move toward less invasive methods, hence improving both service and quality of care.”

ALEXIS JACQUIER

in the light of technical, medical and social progress, the Medical University Centre is de facto helping the city of Marseille open the doors to the healthcare of the future.

Interventional radiology is asserting itself

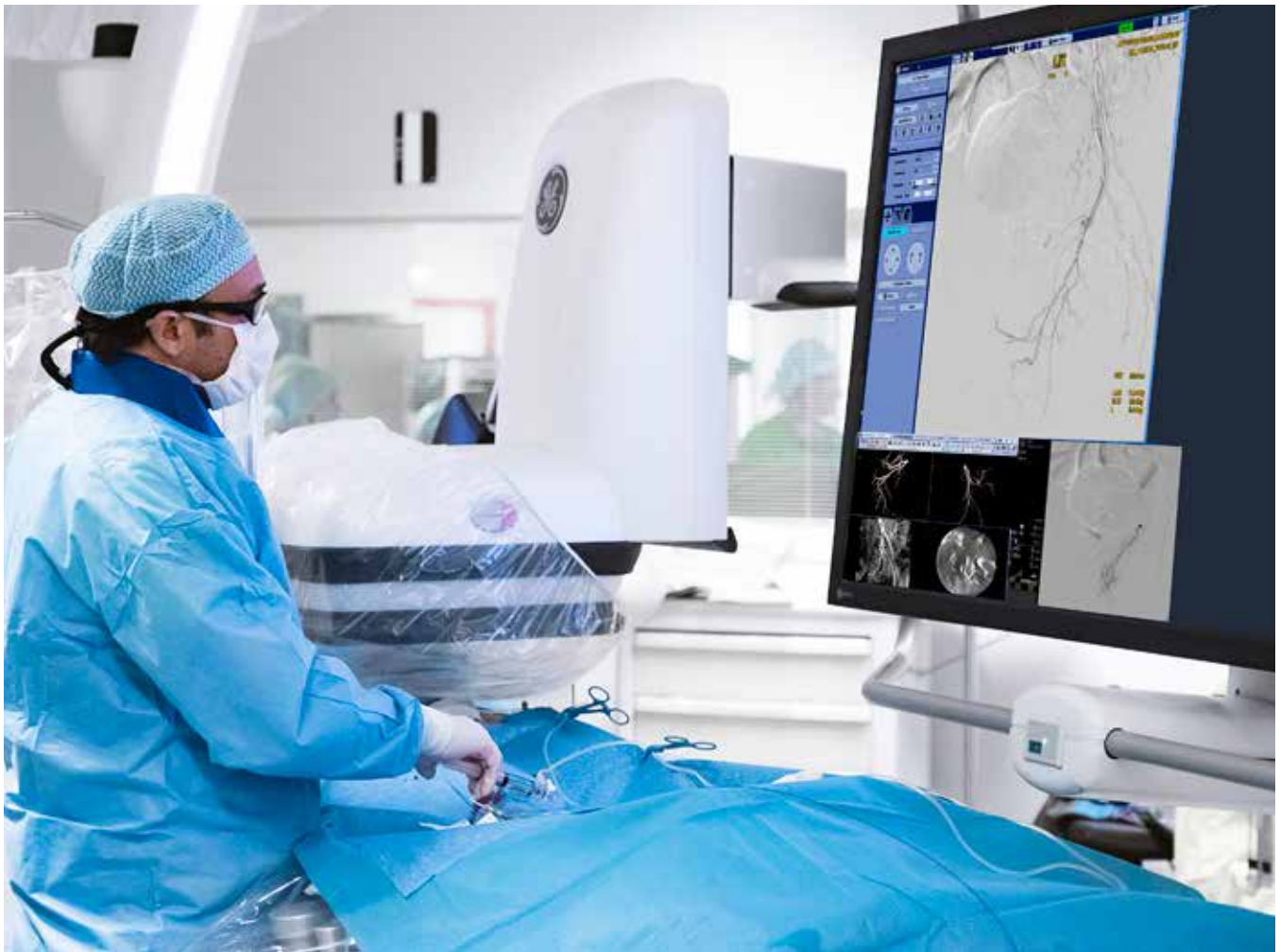When it comes to its new premises destined to host imaging and interventional cardiology units, the hospital has decided to see things big with 9 available rooms, 4 of which are entirely dedicated to interventional radiology. “Previously, working conditions weren’t in line with our professional requirements and with the establishment’s ambitions for interventional radiology, one of its medical offer’s (many) spearheads. Starting from scratch has helped reshape everything. We’ve been able to carve spaces that meet our actual needs, to individualize the intervention sector, redefine some good practices and reinforce quality standards with

LIIE, an experimental template

Forming part of the CERIMED – a platform for research in medical imaging with a European vocation – the Laboratory of Experimental Intervention (LIIE) of Timone is entirely dedicated to preclinical matters of interventional radiology. Working on experimental models and simulators as much as he can, he focuses his research on developing and patenting new activities, technologies and materials that can be used on humans.

The latest example is the development of a new type of stent that can reduce blood flow rather than restore it.

Note that these new devices can be derived from research conducted by the laboratory, but also from partners benefiting from equipment and premises located within the Timone campus.



the aim to ensure optimal care”, notes Professor Vincent Vidal. The Head of Timone’s Interventional Radiology Functional Unit also insists on its expansion capacity, which formed part of project from the very start: “We’ve anticipated a cadastral reserve that can be adapted depending on the growth of our activity and the acquisition of heavy equipment.” This is a paramount precaution to be taken by the hospital, whose interventional radiology department is one of the most prominent in the country, providing all level 1 to 3 interventions, spanning from the mere diagnosis to the most complex procedures. All with a particular emphasis on technical

interventions, increasingly accessible thanks to the new technologies and opportunities offered by the establishment’s new flagship: the hybrid room.

Hybrid room: rethinking care in multidisciplinary teams

By meeting the requirements of an operating theater with permanent access to state-of-the-art imaging, hybrid rooms are spreading to meet the new needs of interventional radiology. “The hybrid room of Timone 2 offers unique image fusion

capabilities”, states Alexis Jacquier. “Images can be adjusted in real-time, using old pictures to better guide the procedures. Such flexibility and refinement allows us to simplify cases that were once complex. These interventions are often carried out in the presence of teams of radiologists, surgeons, anaesthesiologists, cardiologists, etc.” This great progress mainly ensures the effectiveness of patient care in the context wherein patients tend to have longer life spans and the number of chronic pathologies and their comorbidities is exploding.

“Patients benefit from multidisciplinary collaborations in innovative working conditions which allow for more space, improved ergonomics, and precise imaging equipment, all designed to meet this new medical approach. These devices allow us to image the procedures of the future.”

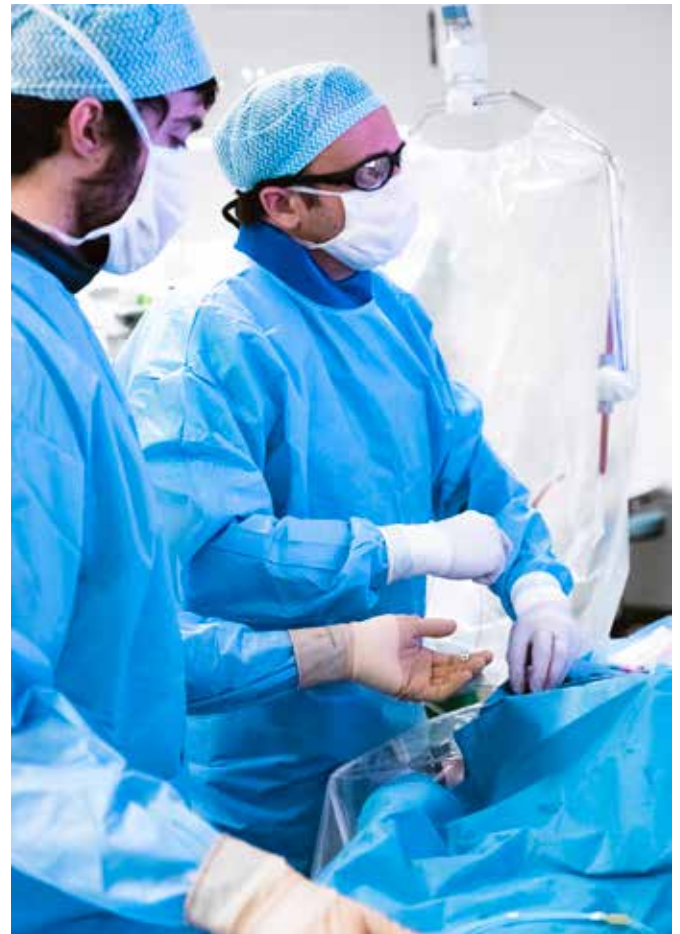
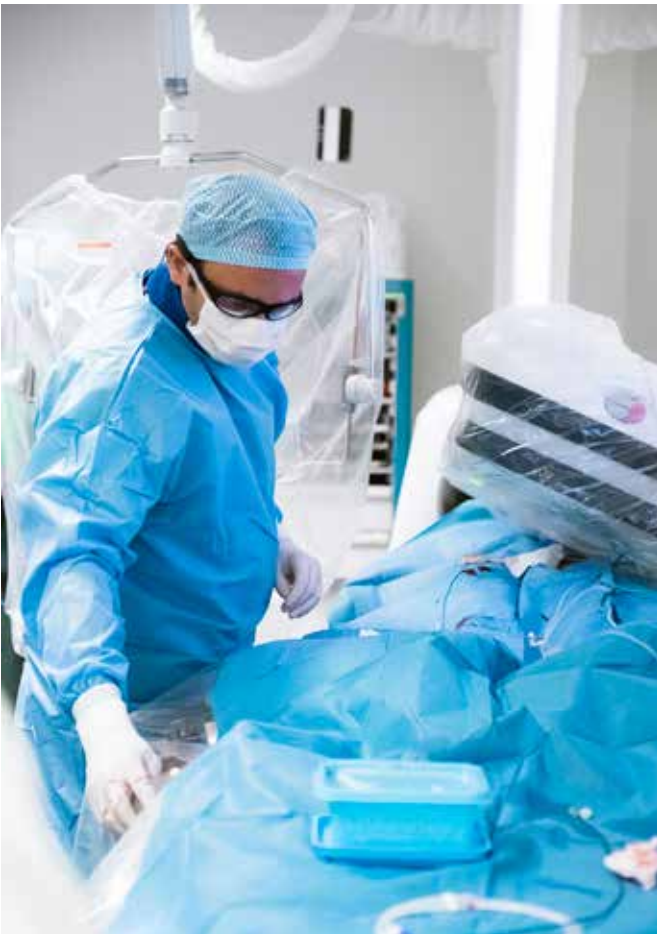Discovery IGS 730, a trigger for innovation

Timone 2's hybrid room owes much of its potential to a next-generation tool developed by GE Healthcare: the

Discovery IGS 730, an original imaging system that combines the power of a fixed gantry with the flexibility of a mobile C-arm. Vincent Vidal shares his impressions: “Both table and C-arm can move... and that makes the whole difference. The device moves automatically, following predefined paths using laser sensors. It is flexible enough to adapt its position to each type of procedure (endo-vascular, cardiac, etc.) and it frees space, if needed, to improve access to the patient.” Another advantage is its wide bore, serving as a simplification of the rotational imagery system which used to be hard to implement. “With

“The high quality imaging technologies and the level of care delivered to patients have led many surgeons to shift from the vascular theatre to the hybrid radiography room.”

PROFESSOR VINCENT VIDAL





Discovery, CBCT acquisition is both simple to achieve and of superior quality, adds Alexis Jacquier. The precision level, similar to that of a scanographic image, is performed directly on the table, allowing finer monitoring and post-intervention control.”

Technology as a springboard for interventions

New imaging technologies developed by manufacturers have allowed interventional radiologists to experiment new fields of application, or even refine old ones. Here are some

examples from Timone : Professor Vidal performs prostate artery embolization (PAE), a technical procedure which consists of blocking prostatic arteries with microbeads to lower blood supply and reduce tissue volume. “Prostatic embolization is a delicate procedure, as vessels in this region of the body are particularly thin. Thorough precision is paramount: in order to successfully block an artery, that artery has to be found, then catheterized. The Discovery IGS 730 and its high-definition 3D imagery allow to interventional radiologists to identify the artery in the Cone Beam CT and to guide the entire procedure. Vascular volume extraction is done by volume rendering and on-screen

image projections are used to help facilitate catheterization. This would have been unthinkable with our former equipment.”

Image fusion has revolutionized TEVAR, greatly contributing to the increase in the number of operations carried out at Timone. Alexis Jacquier insists on his technology’s ability to treat heavily atheromatous patients suffering from comorbidities, altered renal function, among others.

“Guidance with image fusion has the great benefit of decreasing irradiation doses and product contrast injected with the reliability of endoprosthesis release ensured. In short, further

refinement is obtained in the space of shorter intervention time!”

Timone, an engine of interventional radiology

New imaging technologies stand as the cornerstone for the development of interventional radiology practices. Health professionals are aware of this fact and regularly collaborate with industrial players to support R&D, help improve market access and encourage the dissemination of innovations. Like many of their colleagues, the two Timone specialists share their experience with their industrial partners, in the hope of jointly participating in the research, development and deployment of interventional radiology innovations within the institution. This innovation, now called “interventional IMRI”, should allow the image-guided and percutaneous destruction of lesions that cannot be visualized using other techniques.

But don't think that the Marseille Medical University Center only applies innovation in its theaters. It also actively participates in the field's development, through global clinical activity attached to several academic structures, including a joint MRI research unit (CEREMEM-CRMBM, UMR 7339), a DHU (Department of Hospital and University) working on the industrial valorisation of interventional radiology innovation and its LIIE (see box). As for the “human” aspect, Timone has twice set the example by developing the Picline a decade ago, before lately providing volunteer operators with a set of skills. “Delegating the pose of the Picline to

radiographers has turned out to be the most rewarding transformation of practices. Cooperation only strengthens the involvement of radiographers, promoting closer collaboration with doctors” says Professor Vidal, who is behind this concept.

Innovation for health

Another aspect of innovation at Timone is training, with the creation of the School of Embolisation. 20 interns and senior citizens from all over the country are invited for one week to develop their interventional radiology knowledge through practical courses and simulations. This is an original approach that helps broaden the expertise of tomorrow's specialists.

“France is a pioneering and recognized country in interventional radiology. Timone strives to enhance competencies and national innovation through the development of procedures, techniques and original equipment,” conclude the two experts. □

Fu-RI: the interventional radiology of tomorrow

Launched in 2016 on the initiative of Professors Jean-Michel Bartoli, Vincent Vidal and Alexis Jacquier, the international FU-RI annual conference (Future of Interventional Radiology) brings together leading French-speaking representatives of the interventional radiology industry. Its purpose is to gain a foothold on a specific theme, in order to develop joint R&D actions and enhance value in the eyes of managing authorities.

After an initial focus on guiding interventional radiology, the 2017 edition of the 16th and 17th of November will be dedicated to “embolization agents”, with a particular emphasis on research in the field as well as on the presentation of undergoing innovations.

Zero Contrast TEVAR with MRI fusion

Courtesy of Pr. Jacquier, La Timone University Hospital

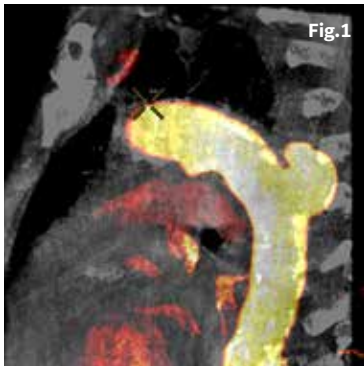


Fig.1

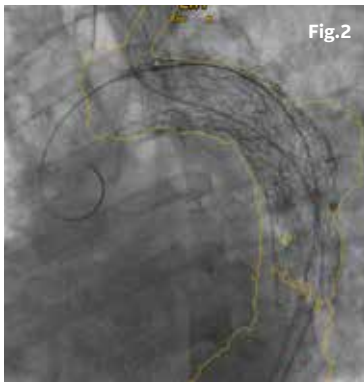


Fig.2

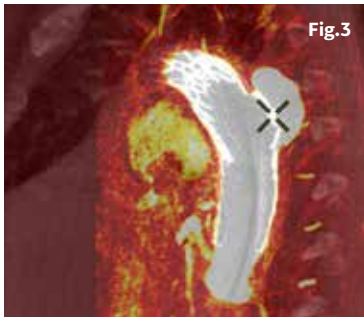


Fig.3

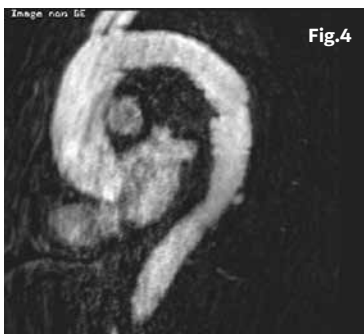

Fig.4

Clinical Challenge

This is the case of a 50-year-old male patient who was admitted to the hospital for the treatment of a rapidly progressive mycotic aneurysm of the thoracic aorta. He had previous history of terminal renal failure treated in 2007 by kidney transplant in left iliac fossa and a recent severe renal failure. Angio MR showed a mycotic sacciform false aneurysm with an increase in size of 4 mm in 15 days. An endovascular intervention guided by image fusion was decided.

Procedure

Planning Phase

Prior to the procedure, as the patient has a severe renal failure, it was decided to do a fusion between MR and fluoroscopy to guide the insertion of the catheter and the endograft. As bones are not visible on MR, registration between MR and fluoroscopy cannot be done directly under fluoroscopy using 3D/2D registration. It has been decided to use a 3D/3D registration workflow between the pre-op MR and a CBCT (Cone Beam CT) done at the beginning of the intervention, then the aorta segmented on the pre-op MR is displayed directly on the fluoroscopy, accurately registered with respect to the patient anatomy.

The first part of the workflow consisted of registering MR and non-injected CBCT. Once the CBCT is performed, a landmark-based registration is then enabled by the Integrated Registration protocol of Volume Viewer (Advantage Workstation). Several landmarks have been chosen (Fig.1). Among them, the ostium of the left subclavian artery and other

remarkable points of the aneurysm sac achieved in both rotation and translation over the live fluoroscopy to ensure accuracy.

Guidance Phase

A 22 French introducer sheath was then pushed in the abdominal aorta. A first stent-graft was positioned on the distal part of the lesion (Fig.3). A second stent graft was positioned to cover the proximal part of the third segment of the aorta, at the distal part of the left subclavian artery ostium (Fig.4). The proximal and distal ends of the stent graft were angioplastied with a trilobed balloon.

Assessment Phase

As no contrast medium can be injected to assess the endograft position with respect to the aorta wall, a post-TEVAR CBCT was performed.

CBCT was then automatically fused to the pre-operative MR, using the registration that was made at the beginning of the case.

Results

Exclusion of the false mycotic aneurysm was performed 5 days later using MR, which revealed a complete exclusion of the lesion.

Fig.1 MR aorta superimposed on the pre-TEVAR CBCT. This segmentation is then kept as a "mask" that will be displayed on top of the fluoroscopy during the intervention.

Find more on GE Cares

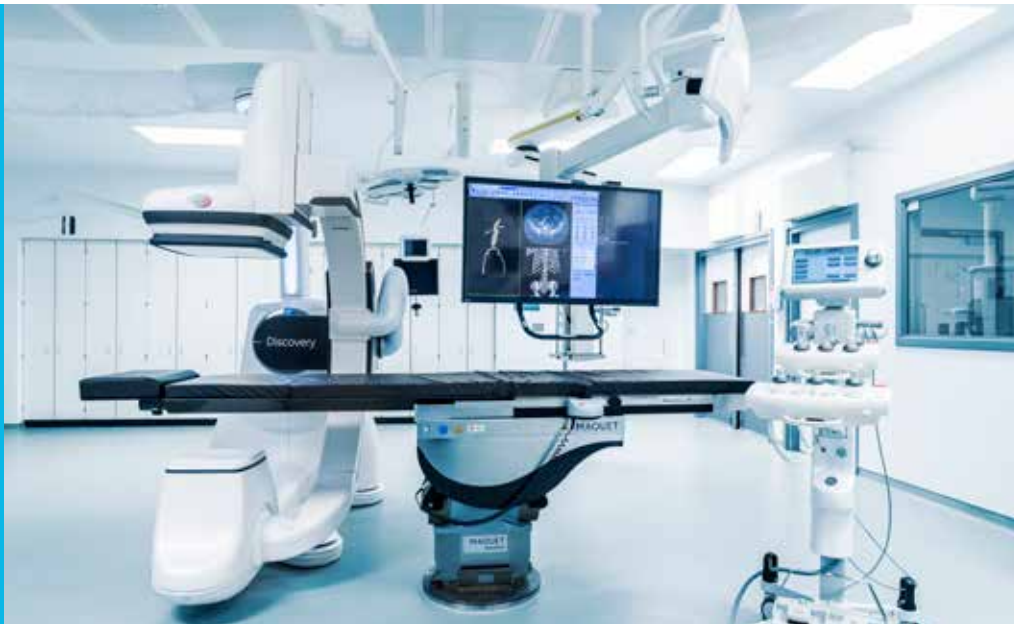

Contact

Dustin Boutboul
dustin.boutboul@ge.com

A photograph of two surgeons in a hybrid operating room. They are wearing blue scrubs, surgical masks, and blue bouffant caps. The surgeon on the left is wearing a head-mounted microscope. They are both focused on a patient's leg, which is illuminated by a bright surgical light. The background is a blurred clinical setting.

A brand new hybrid room to treat patients in greater Manchester



With the advent of complex minimally invasive vascular procedures, such as endovascular aortic aneurysm repairs, improved imaging accuracy and safety are needed. Along with hygiene requirements, this need has led to the development of hybrid operating rooms in hospitals with cutting-edge vascular and cardiac activities. The vascular team at University Hospital of South Manchester tells us all about their new hybrid operating rooms.

University hospital of South Manchester (UHSM) in Wythenshawe is a major acute care teaching hospital, offering district general hospital services and also specialist tertiary services to the population of greater Manchester, with a large cardiothoracic and vascular center and a transplant center.

Nine months ago, UHSM opened two new hybrid operating rooms (HOR) equipped with the Discovery™ IGS hybrid angiography system. The HORs are used by many specialties: mainly vascular surgery and vascular radiology, but also cardiology for TAVI procedures. In a couple of months, UHSM is going to expand the use of the hybrid rooms to the urology team to enable joint procedures with radiology for cryotherapy procedures.

UHSM IN NUMBERS:

- 6500 staff
- 634000 immediate population served
- £476 Mio turnover per year
- 944 beds
- Among top 20% of trusts in England for staff engagement



Delivering the best possible care

Donna Young, Director Manager for Surgery at UHSM, explains why UHSM invested in a hybrid room, the challenges they faced with staff training and the benefits that came out of the new hybrid room.

“The main reason for investing in a new hybrid room was to improve the quality of care for patients. What that means is that we are now performing minimally invasive procedure on patients, so we are operating on patients on a daily basis, whereas historically we would admit these patients into a bed, and they would potentially stay for two or three days. Overall, we are now reducing the length of stay for suitable cases, and the HOR has allowed us to do that for the first time ever.”

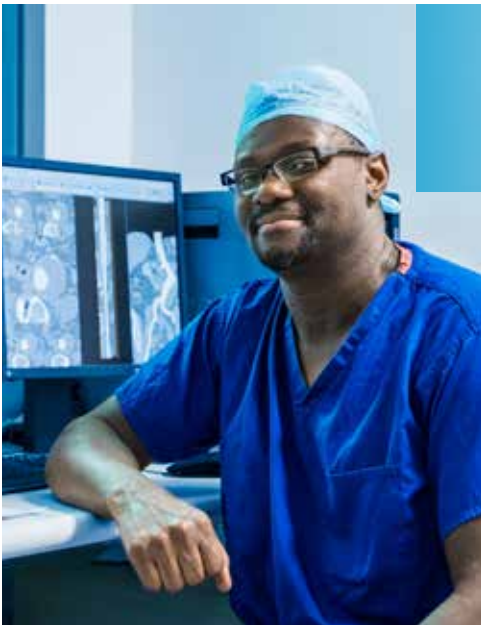“Previously, vascular surgery had access to a single theater which was not aligned in shape or form with the standards of HOR. Now we have two theaters where we can perform the procedures that we need in vascular surgery and cardiology. We also plan to expand to urology. Our waiting time is reduced because we have two rooms now that can function at that level, so we can treat the patients more quickly as a planned procedure rather than waiting too long and having the patients admitted in emergency.”

“I would say, the biggest challenge in introducing the HOR was to commit to a robust training program for the staff, because the HOR was new to everybody, whilst trying to maintain business as usual and to manage emergency cases that were still coming through the door. It is very difficult to commit to training, while balancing daily priorities for patients. We had to make sure that staff were released from their duties to attend training and simulations supported by GE and Maquet, and then teams went to work in a different local trust to experience a hybrid room, but it was not as new as ours. Even after 6 months, we’re still learning because the room is not only used for planned procedures between 9am and 5pm, but also after hours for emergency procedures. So, everybody needs to be trained, not only staff working in that room, but also on-call teams, including colleagues from other trusts. We found that to be quite a steep challenge, but staff has responded to it and absolutely loves working in the room now.”

“There is pressure each year for the organization to save money. We can now deliver minimally invasive procedures in the hybrid room, which reduces requirement for beds, and helps bringing hospital costs down.”

“There is pressure each year for the organization to save money. We can now deliver minimally invasive procedures in the hybrid room, which reduces requirement for beds, and helps bringing hospital costs down. We are already seeing early results in our EVAR patients’ length of stay, and expect that it might grow even further.

To make this sort of investment in a brand new HOR for the hospital sends a really important message to patient and staff. It suggests that we are serious about delivering quality care. It is also critical for staff retention. The teams love working in a state of the art environment, knowing that they are delivering the best possible care.” □



Perform complex EVAR procedures in one go

The department of vascular surgery of UHSM performs a variety of vascular interventions, such as open aneurysm repair, endovascular aneurysm repair, all range of peripheral interventions, carotid stenting and arteriovenous malformations. Dr. Dare Seriki is a consultant vascular radiologist at UHSM, specialized in challenging EVAR procedures.

Tell us about your new hybrid operating room at UHSM

We're quite lucky at UHSM. We were one of the first hospital in the UK to have the Discovery system which has been integrated with the Magnus table from Maquet. This means that we can perform endovascular procedures using an endovascular table and that open procedures can be performed on a state-of-the-art breakable table that is suited for these procedures.

What has changed in your practice since the opening of the Discovery IGS 730 hybrid OR?

The use of the Discovery system in the hybrid theater has changed our practice quite dramatically. Before the hybrid was opened, we performed our combined procedures with vascular surgeons in their normal theater using a portable C arm. There was always a risk of it overheating and it was difficult to get steep angulations, so we were limited in the range of procedures that we could take. Complex procedures really were very difficult to perform unless you had two C arms

available. So now, we're taking on much more challenging procedure and a lot more combined cases. For example, we'll perform common femoral endarterectomy, and then we'll do peripheral intervention on the leg, and we'll even go down to do ballooning procedures.

What benefits do you see in using the Discovery IGS hybrid OR?

First, the Discovery is not in a fixed position; it can be positioned anywhere within a horse shoe shape configuration. But if you're performing a purely open procedure, then you can park it in several parking positions, which means that the surgeons have unlimited access to the operating theater.

The Discovery is a state-of-the-art imaging system with advanced image fusion solutions, which means that we can plan our endovascular procedures beforehand from a CT or MR dataset, and then use that information to guide the intervention. Because procedures are planned beforehand, you know exactly what you're going to do before

"The throughput is improved so we can sometimes perform three EVAR procedures in one day, and be finished by five o'clock"

you enter the operating theater. Therefore, the procedure time itself is reduced, and most importantly the radiation delivered to the patient and to the staff is reduced¹. And this means the procedure is much safer for everyone involved. You can also reduce the amount of contrast that you are giving to the patient. Overall, it improves the procedure in terms of efficiency, radiation dose, contrast usage, and procedure time.

What are the most important outcomes after 6 months use of the Discovery IGS hybrid OR?

I'd say the major impact is that we are now able to treat all the patients who present themselves to UHSM with complex pathologies without compromising any aspect of their care. We're performing more prolonged procedures under general anesthesia, and we know that we can image

1 Impact of Hybrid rooms with image fusion on radiation exposure during endovascular aortic repair, Eur J Vasc Endovasc Surg. 2014 Oct;48(4):382-90

without encountering problems. There's no compromise at all.

Did the hybrid operating room change the way you perform your complex cases?

The use of Cone Beam CT has been accelerated since the opening of the hybrid OR. We use it to perform a completion angiogram at the end of our EVAR procedures to verify that the patient does not have an endoleak and that the graft is situated appropriately. We can be more confident that we can discharge the patient without performing further follow-up imaging during that admission, the patients can go home, and we're confident to

have them enter a normal ultrasound surveillance program.

How would you describe your first months using Discovery?

I would say that there is a steep learning curve and that staff training is very important. But once you're over the learning curve, the staff really enjoys working in this state-of-the-art facility. The procedures are done a lot quicker and the throughput is improved so we can sometimes perform three EVAR procedures in one day, and be finished by five o'clock. And for everybody it's the job satisfaction, you know that you're performing the procedure in the safest

possible situation and environment for everybody, so you're not compromising between the anesthetic, surgical or endovascular approach. I would recommend Discovery in hybrid theaters. It is state-of-the-art technology, it is relatively simple for the radiographers to use, the training program is approximately one week for those that are used to using endovascular rooms, it is intuitive, it is simple, and I would recommend it to anybody. □



The benefits of the hybrid room for combined procedures

The hybrid ORs are used by the cardiac surgery and vascular surgery departments for open as well as endovascular procedures.

Mr. Jonathan Ghosh, vascular surgeon, and Mr. Isaac Kadir, cardiac surgeon, both working at UHSM performed their first combined procedure in the hybrid room together and shared their experience.

Mr. Ghosh, what type of procedures do you perform in the HOR?

JG: With our Discovery IGS 730 hybrid room with the Magnus table from Maquet, we perform a full range of vascular procedures. I do all my open operations, from carotid surgery and open aortic surgery to peripheral

bypass surgery. About 50% of my peripheral work is in combination with interventional radiology. What has been of particular interest to me is the opportunity to do more complex work with other specialties, such as cardiothoracic surgery, plastic surgery and surgical oncology. The HOR allows us not to have to compromise any aspect

of the operation for combined cases. We have excellent imaging together with the advantages of a modern operative ward.

What are the benefits of having a mobile system in the hybrid OR?

JG: We built it to have different

working positions and to be able to fully retract the gantry when we're doing open surgery, because it opens up the full operating environment. But also when we're doing combined cases, it allows for easy access for the open surgical part of the treatment as well as excellent imaging for the endovascular part of the treatment. It's very easy to change the table tops with the Magnus system from Maquet, so we use the flat table top for all our endovascular work (our EVARs, TEVARs and lower limb reconstructions), and for the open cross and aortic surgery, we move to the breakable table top.

Do you routinely use image fusion?

JG: We do all our EVARs and TEVARs in the HOR using image fusion. The EVAR

ASSIST 2 solution (GE Healthcare) enables easy planning and good communication with the gantry to guide the procedure. The image fusion reduces our screening time; our radiation dose has fallen down for each case, and our contrast usage is more efficient¹. We also routinely use cone beam CT as a completion image. This allows us to do a 360° assessment of the stent graft, make sure there's no deformation of the prosthesis nor any endoleak.

What are the key outcomes after 6 months of using your new hybrid rooms?

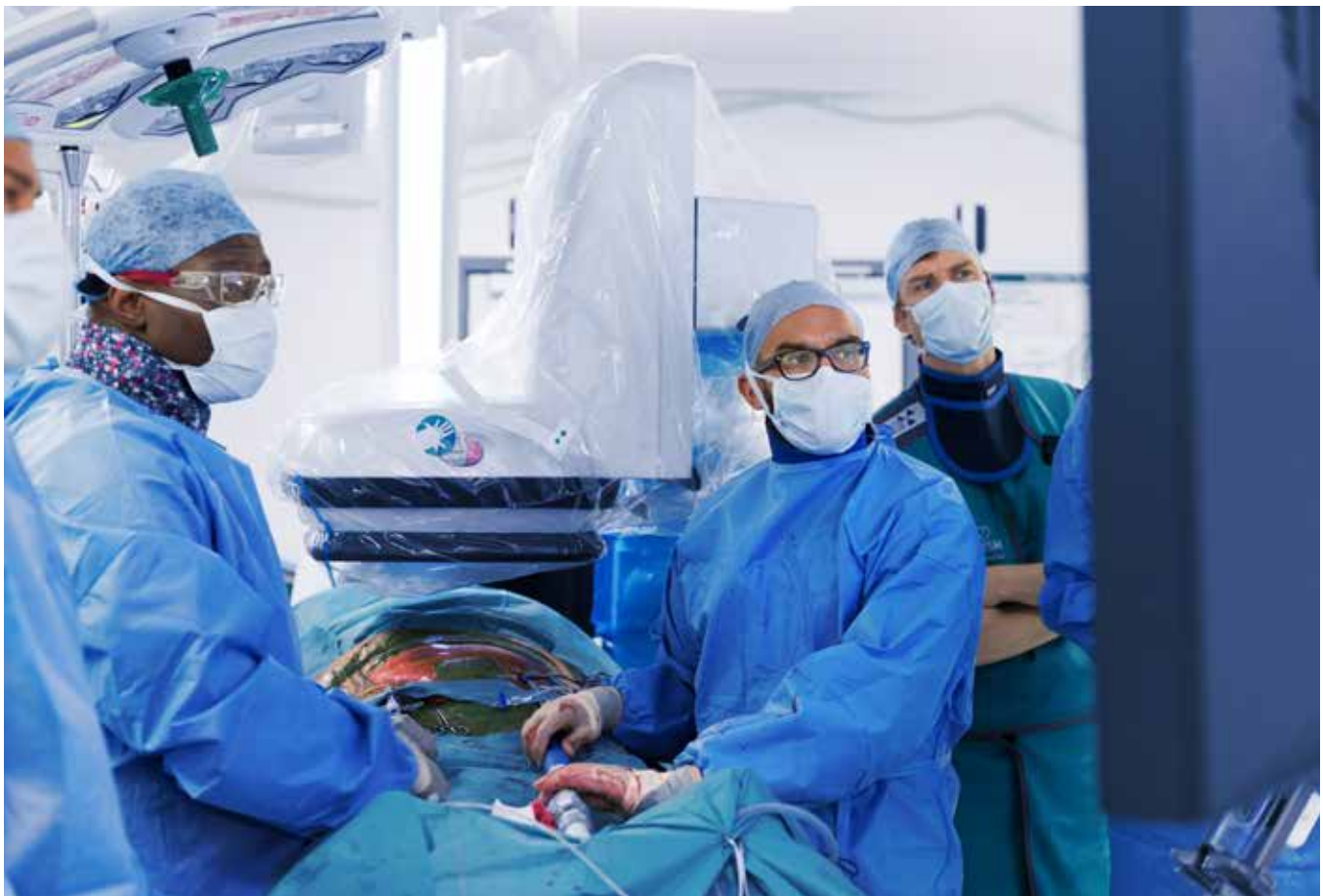JG: We are now able to perform more complex cases and treat more challenging anatomies thanks to the

"The image fusion reduces our screening time; our radiation dose has fallen down for each case, and our contrast usage is more efficient."

expert imaging level. It provides an excellent treatment to patients and the patient flow has become more efficient. It is a fabulous working environment to operate in, the collaborative work that we do is improved, and it's just a pleasure to operate in that room.

Can you describe today's combined procedure?

JG: We operated on an 81-year-old gentlemen that had a very significant coronary lesion, a rapidly enlarging



abdominal aortic aneurysm, both of which needed treatment and a background of interstitial lung disease. So, he had quite a limited physiological tolerance and we felt unsafe to treat his coronary artery in isolation because of a risk of rupture from his aneurysm. And treating his aneurysm without stressing his coronary artery would have been unsafe.

IK: This gentleman had an extremely tight proximal right coronary artery lesion. His left coronary artery was a left main stem lesion with a very significant lesion further down his mid left anterior descending artery (LAD). This left main stem lesion extended into his circumflex artery. So, he needed a coronary artery bypass grafting with 3 grafts as well as an endovascular stenting of his large infra-renal abdominal aortic aneurysm. After appropriate multidisciplinary meetings, we decided that a combined approach was best for him.

How would you have done it

without the hybrid room?

IK: Without the hybrid room, we would have had to do this in a sequential manner. The traditional way, which is often debated, is that we would have done either his coronary artery surgery first, followed by a short period of recovery and then have his aneurysm dealt with, or we would have treated his aneurysm first. Now, if you were to have any one of these procedures, there would be risks with the disease which is left untreated. For example, following coronary surgery, there is a high rate of rupture of abdominal aneurysm which are this large. If you were to deal with the abdominal aortic aneurysm first, in the presence of such coronary lesion, then the patient would probably have a myocardial infarction at the time of the procedure or while waiting. So, I think with this set up that we have now, the patient is ideally suited. And there are many other advantages, the patient has only one hospital stay, one anaesthesia and his period of recovery

is shortened overall, because hospital stay of this patient will just be what his usual hospital stay following a coronary artery surgery would have been: 4 to 5 days. And that's the end of it. He would continue to recuperate at home, and there would not be any separate added recuperation as a result of the endovascular procedure that he's had.

JG: We were able to do perform combined coronary artery bypass and EVAR. The coronary artery bypass was done in conventional manner with the advantages of working in a modern operating environment and the EVAR was performed immediately after under the same anaesthesia with excellent imaging and the benefits of a fixed imaging system, such as reduced radiation and screen time. I think we provided the patient with an excellent operation. □



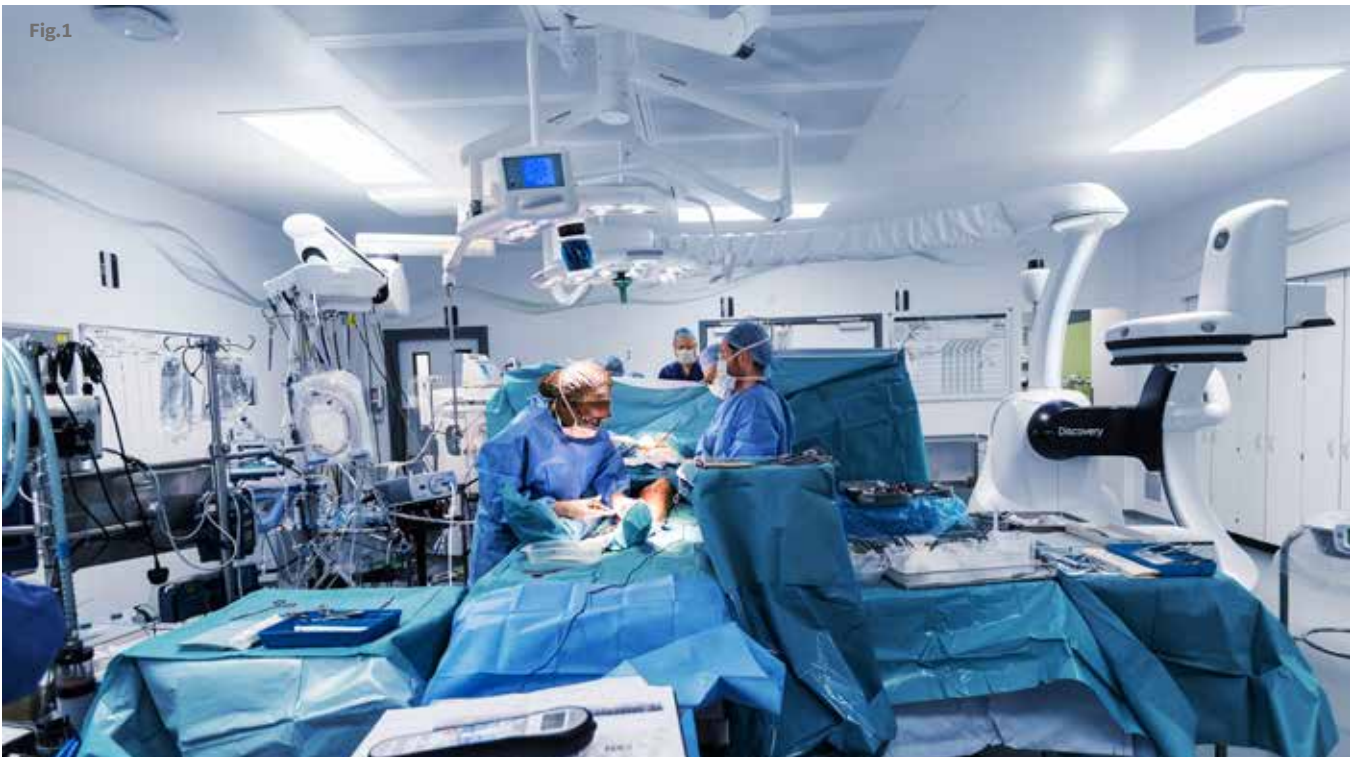Mr. Kadir, as a cardiac surgeon, can you envision other multidisciplinary procedures that can be done in the HOR?

IK: Yes. As a matter of fact, we are planning another similar procedure, except that this patient needs to have a TAVI. He has an aortic valve stenosis, and he also has a large abdominal aortic aneurysm, which has enlarged by over one cm in the past 6 months. It's above the threshold for traditionally treating this, so that's another procedure that we have planned to do in the hybrid room. I have also been operating in the theatre, not only for hybrid procedures, but also for TAVIs

"I think we provided the patient with an excellent operation."

where I needed imaging for direct aortic access. Although it's not a combined procedure, it is a procedure which is well suited for the hybrid room, whereby the patient needs a TAVI and does not have a peripheral access, so you need to do a formal mini sternotomy to access the aorta and then have the imaging to do a successful TAVI. So, it worked well in that situation also. Certainly, this is the way forward, this is the ideal use of a hybrid theatre in my opinion. □

Fig.1



The Discovery IGS 730 hybrid operating room equipped with the Magnus OR table system from Maquet.

Fig.1

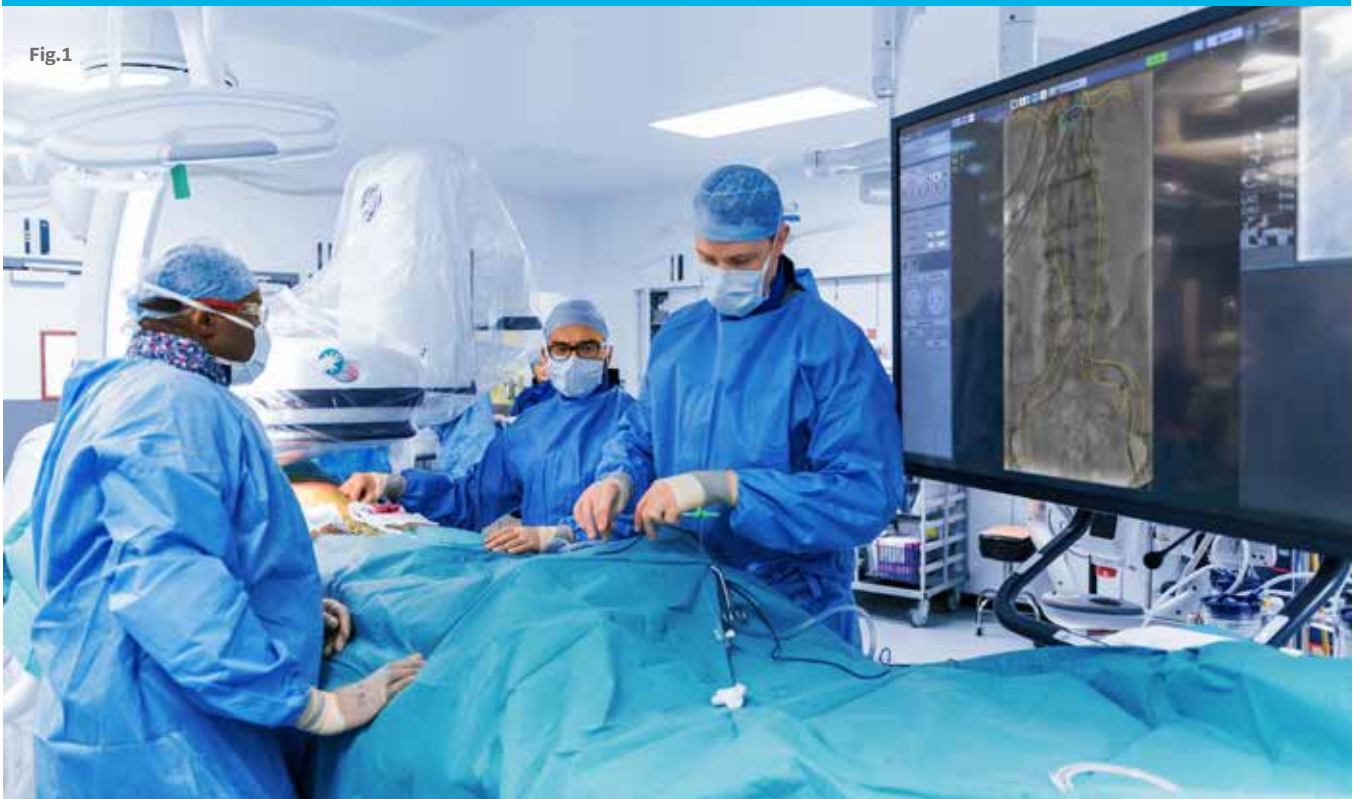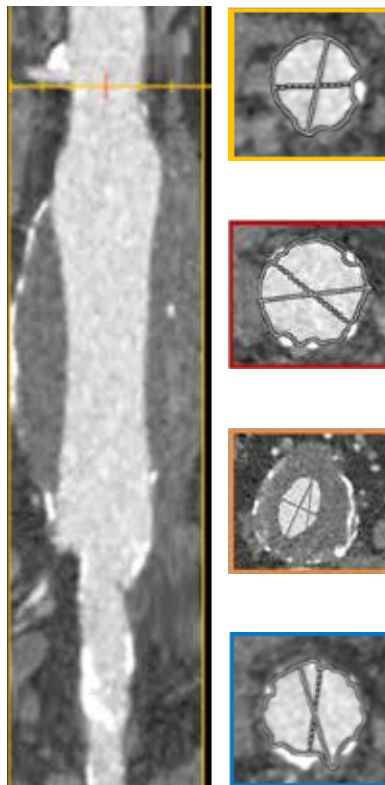

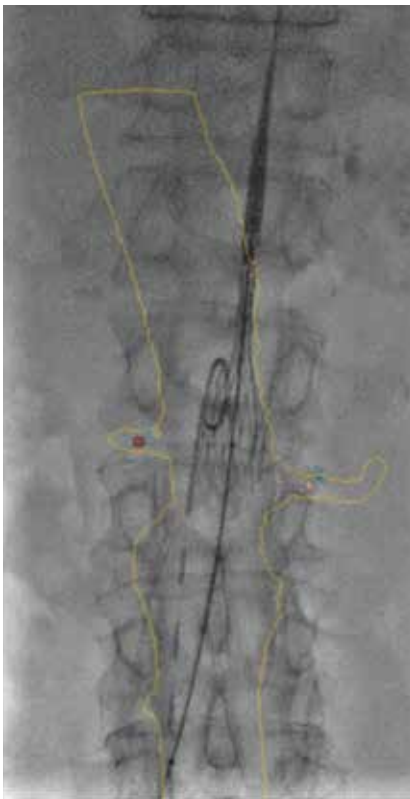
Fig.1 Open surgical procedure configuration, with the breakable table top and the angiography system parked in a corner of the room

Fig.2 Endovascular procedure configuration, with the endovascular table top and the mobile angiography system moving freely around the table

Endovascular Aneurysm Repair with short conical neck on Discovery IGS 730 Maquet

Courtesy of Dr D. Seriki, University Hospital South Manchester (UK)



Lumen view of Right Iliac, showing the conical shape of the neck; cross sections at different levels:

Yellow: below most inferior renal (20x23mm)

Blue: 13 mm below renals (23x29 mm)

Red: 16 mm below renals (27x31mm)

Orange: aneurysm size (62.2 mm)

Clinical Challenge

An increasing number of patients are rejected for EVAR due to hostile neck anatomy. Short conical aneurysm necks are not suitable for conventional stent grafting, as they are associated with higher risks of post-procedural complications (eg, proximal endoleak, stent graft migration). Operators need to accurately measure the aneurysm and select the most appropriate device and leverage the planning during the procedure to reduce procedure time, radiation dose and contrast.

Solution

The procedure was performed with a Discovery IGS 730 system equipped with Maquet™ table and the EVAR ASSIST package.

A 34 mm stent graft device was chosen. The patient was referred from a neighbouring hospital thanks to our vast experience in this device (65 cases).

Clinical case

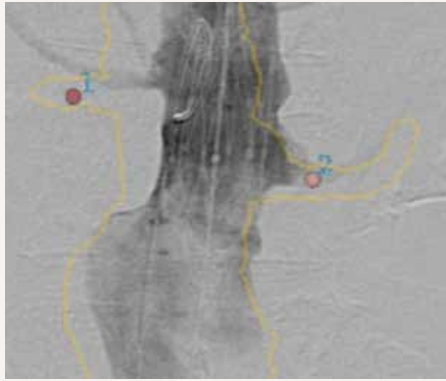
Patient History

A 81 years old patient was discovered an incidental 6.3 cm aneurysm during investigation for renal calculi.

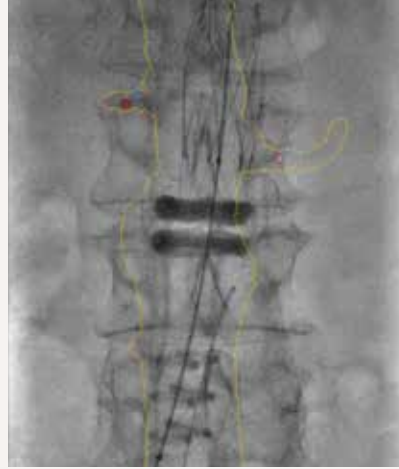His comorbidities are chronic obstructive lung disease, reduced mobility and ex-smoker.

The patient has stage 4 renal impairment (estimated glomerular Filtration Rate eGFR 25).

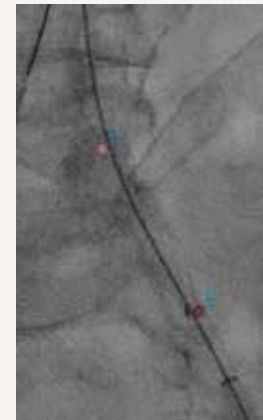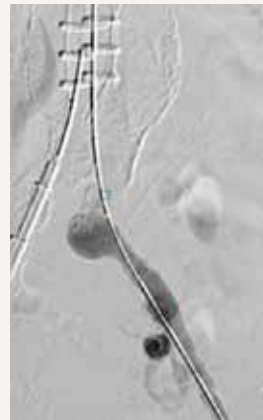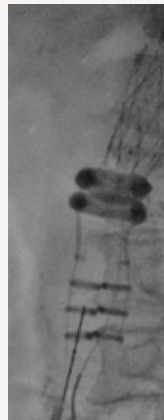1



A quick 5 mL dilute injected DSA is used to refine the registration of the 3D model on the lowest renal. The fabric markers are being placed higher than usual, in the middle of the renal ostium, to ensure that the sealing ring is above 13 mm below the lowest renal, given the diameter ap-proaching 30 mm at this level.



The fixation stent is released and the polymer is injected. The contralateral limb is cannulated within 14 minutes in order to mould the sealing ring at the appropriate time. A 5 mL dilute contrast DSA is used to register the fusion markers on the origin of the internal iliac artery, left iliac limb is then deployed.



Procedure

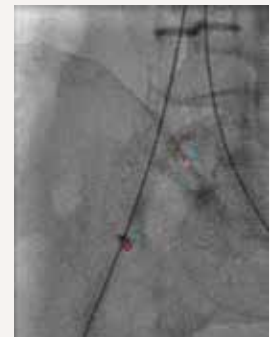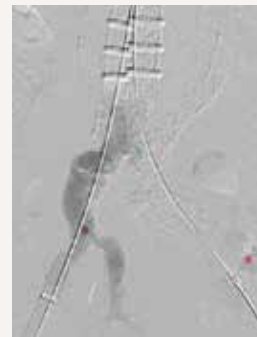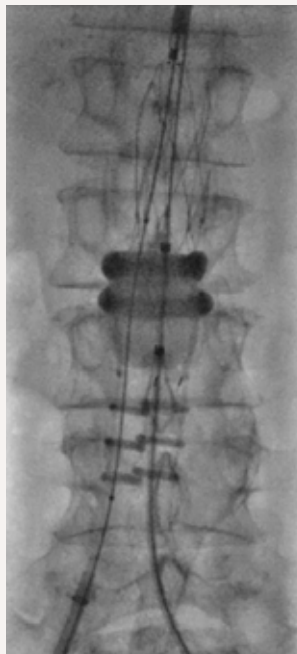CT Planning on Advantage Workstation (AW)

After bone removal and automatic center-line creation, the AW provides automatic measure of the diameters below the lowest renal (at 0, 13 and 16 mm), showing the short conical neck. 3D rendered bone and vessel models are automatically extracted from the CT, on which the operator adds markers at the renal ostia, aortic bifurcation and iliac bifurcation ostia.

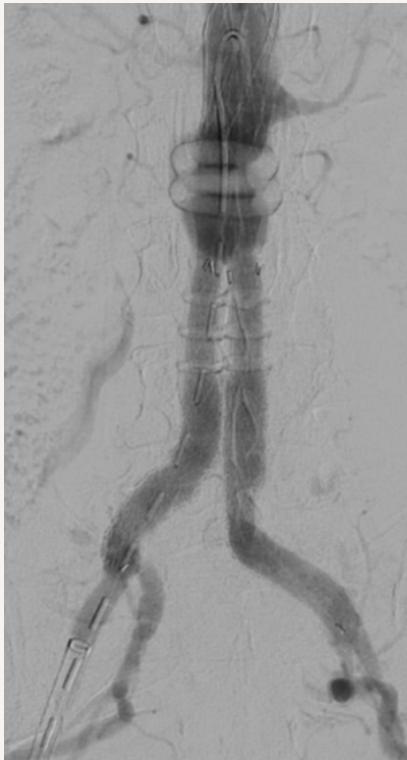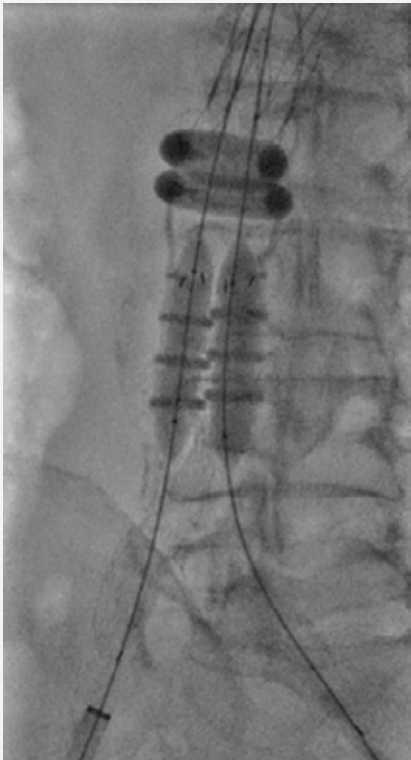
Procedure

The 3D bone model is registered on the fluoroscopy with two views. The device is inserted at the level of the renal arteries without contrast injection.

2



The sealing rings are then moulded by a balloon. The right iliac limb is deployed after DSA registration of the fusion markers on the origin of the right internal iliac.



Both iliac limbs are then moulded by balloons. A completion angiogram at half strength contrast is finally performed (the figure is a peak op)

Conclusion

The procedure time was 2 hours from start to finish. The outcomes were successful: the duplex scan performed on the following day showed no trace of endoleak.

The Discovery IGS 730 equipped with EVAR ASSIST allowed to treat this patient in a safe environment, using reduced contrast and screening times¹.

Total DAP (Gy.cm ²)	21.2
Total AK (mGy)	176
Fluoro Time (s)	21
Contrast media (ml)	50
DSA runs	5

About

University hospital of South Manchester is a major acute teaching hospital, offering district general hospital services and also specialist tertiary services to the population of greater Manchester, with a large cardiothoracic and vas-cular center as well as a transplant center.

Find more on GE Cares



Contact

Emmanuelle Majus
emmanuelle.majus@ge.com

¹ Impact of Hybrid rooms with image fusion on radiation exposure during endovascular aortic repair, Eur J Vasc Endovasc Surg. 2014 Oct;48(4):382-90

GE CARES Community

Learn how to capitalize on online resources to facilitate trainings and increase your professional skills.

GE Cares is a community where you **connect** with healthcare professionals, **share** your experience, publish contents and **learn** new techniques by having a direct access at the clinical webinars, protocols, clinical cases helping you improve your skills. You can also contact GE application specialists whenever you need to ask a question or get supported.

GECARES.COM



CONNECT

Connect with other healthcare professionals and grow your network. Interact with key opinion leaders and view their publications.



SHARE

Share your experience, publish content and stay up to date with the latest clinical trends shared by your peers.



LEARN

Learn new techniques and increase your skills in your daily practice. Access online trainings, educational contents, clinical webinars built by experts for experts.

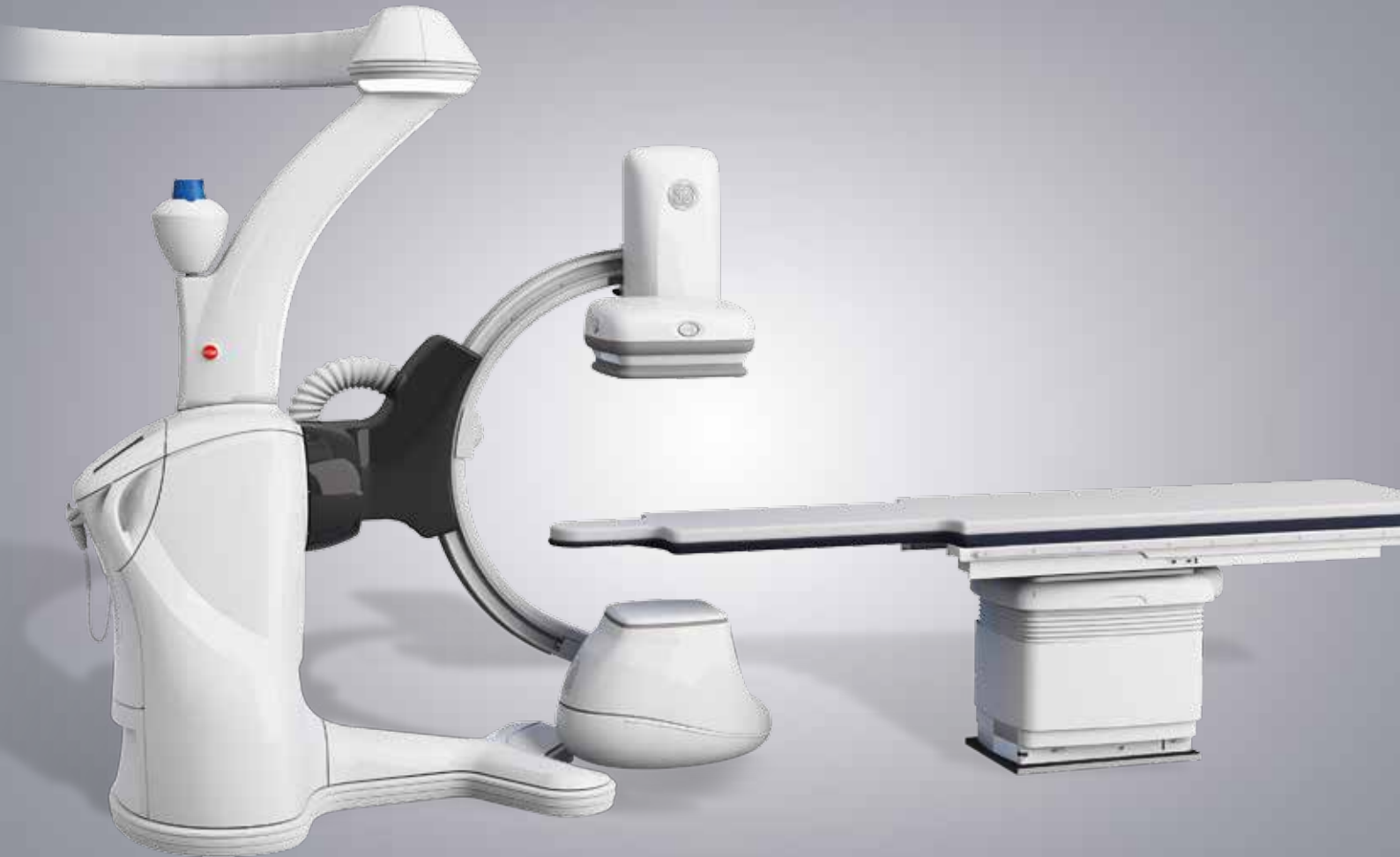

Join us now on **GECARES.COM**



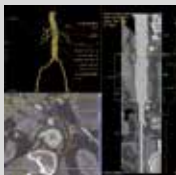
Discovery* IGS with ASSIST

Rediscover space and movement



www.gehealthcare.com

Plan



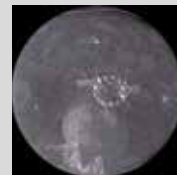Plan your EVAR procedure with a dedicated set of tools to perform key anatomical measurements, size the endograft and save key information for fusion imaging during the procedure.

Guide



EVARVision provides 3D fusion guidance for EVAR, including the vessel outline, ostia contours and stored optimal angulations to help guide your procedure for precise device placement.

Assess



Acquire a high definition cone-beam CT, Innova CT HD, to display the information in oblique views to assess device deployment and the presence of potential endoleaks.

*Trademark of General Electric Company



GE Healthcare

GE Healthcare provides medical technologies and services to help solve the challenges facing healthcare providers around the world. From medical imaging, software, patient monitoring and diagnostics, to biopharmaceutical manufacturing technologies, GE Healthcare solutions are designed to help healthcare professionals deliver better, more efficient and more effective outcomes for more patients.

GE Healthcare is betting big on digital; not just connecting hospital departments and physicians more effectively, but utilizing the masses of data from its equipment and the collaboration between hardware and software – “digital industrial” – to help clinicians make better care decisions. Sensors, software and smart data analytics are converging to enhance GE Healthcare’s offerings not just in diagnostics, but also pathology, gene sequencing and even hospital asset tracking.

GE interventional imaging systems help you plan, guide and assess your wide range of interventional procedures precisely and efficiently. The new generation of ASSIST advanced applications allow you to extend your clinical capabilities and help simplify and streamline your procedural workflow.

<http://www.gehealthcare.com/>