

# ViewPoint 6

GE Healthcare



Jason Carotid  
14222 Central Ave  
New York NY 422211

Date: 11/26/2010

## Extracranial

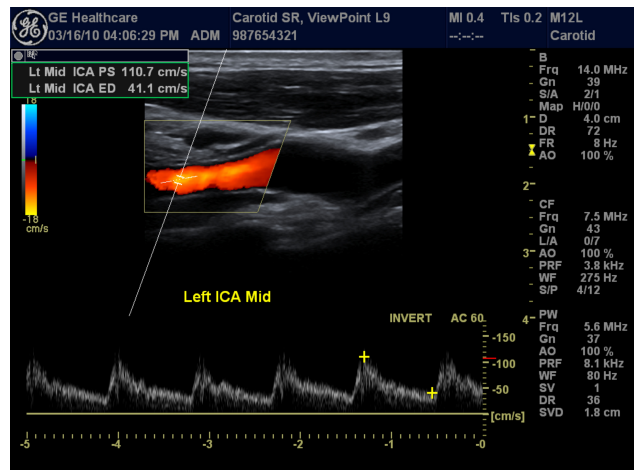
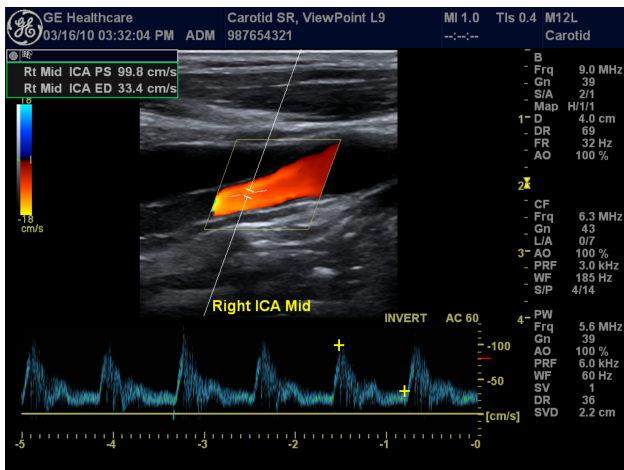
**Indication** Vertigo/dizziness.  
**History** Smoking: yes.  
**Method** LOGIQ E9. Good view.  
**Results**

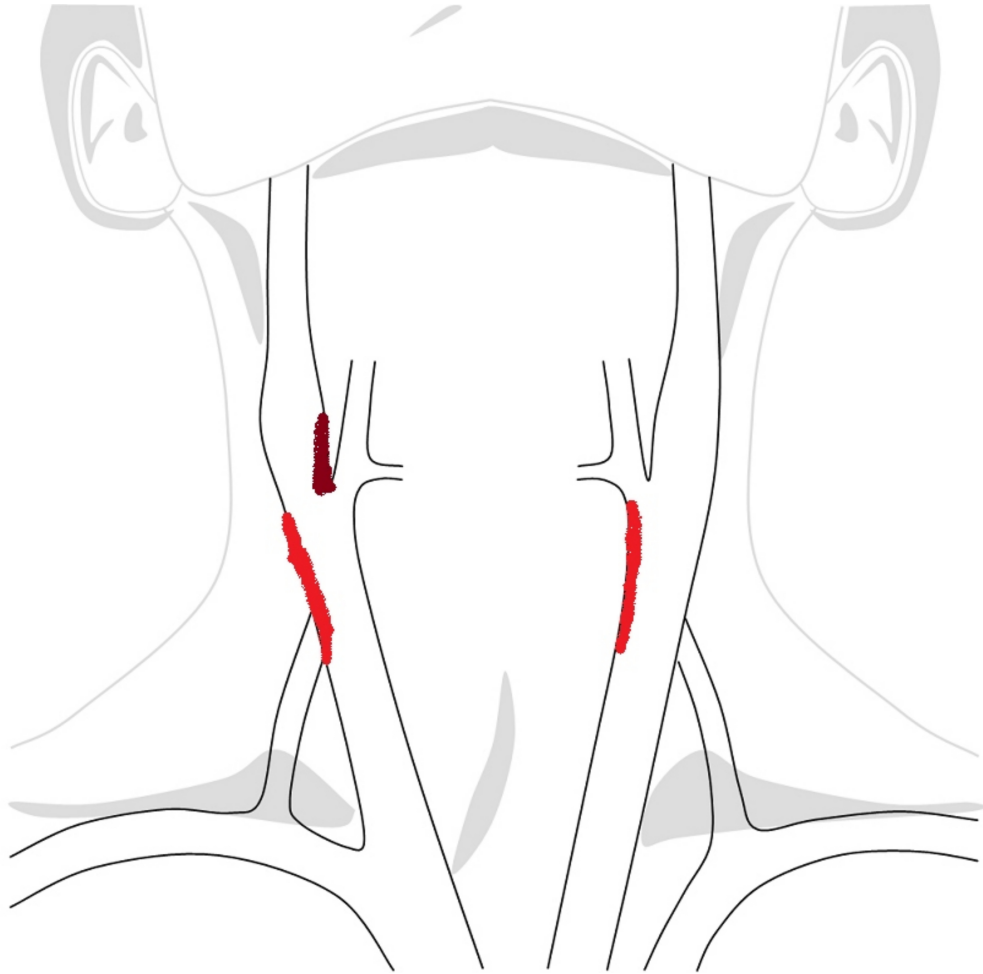
	RIGHT		LEFT	
	PS cm/s	ED cm/s	PS cm/s	ED cm/s
CCA prox	99	23	108	29
CCA mid	94	23	89	26
CCA distal	66	22	74	23
ICA prox	65	25	102	44
ICA mid	87	40	99	53
ICA distal	103	44	89	43
VERT	68	22	60	27
ICA / CCA	1.6		1.4	

	RIGHT	LEFT
ICA Stenosis	normal	normal
ICA Plaque	homogeneous	homogeneous
CCA Plaque	calcification	no calcification
VERT	antegrade flow	antegrade flow
SUBC	normal flow	normal flow

**Impression** No hemodynamically significant No significant stenosis at the carotid right bifurcation.  
No significant stenosis at the carotid left bifurcation.

**Follow-up** A repeat evaluation is recommended in one year.





B. Miller  
Sonographer

Dr. B. Winter  
Performing physician