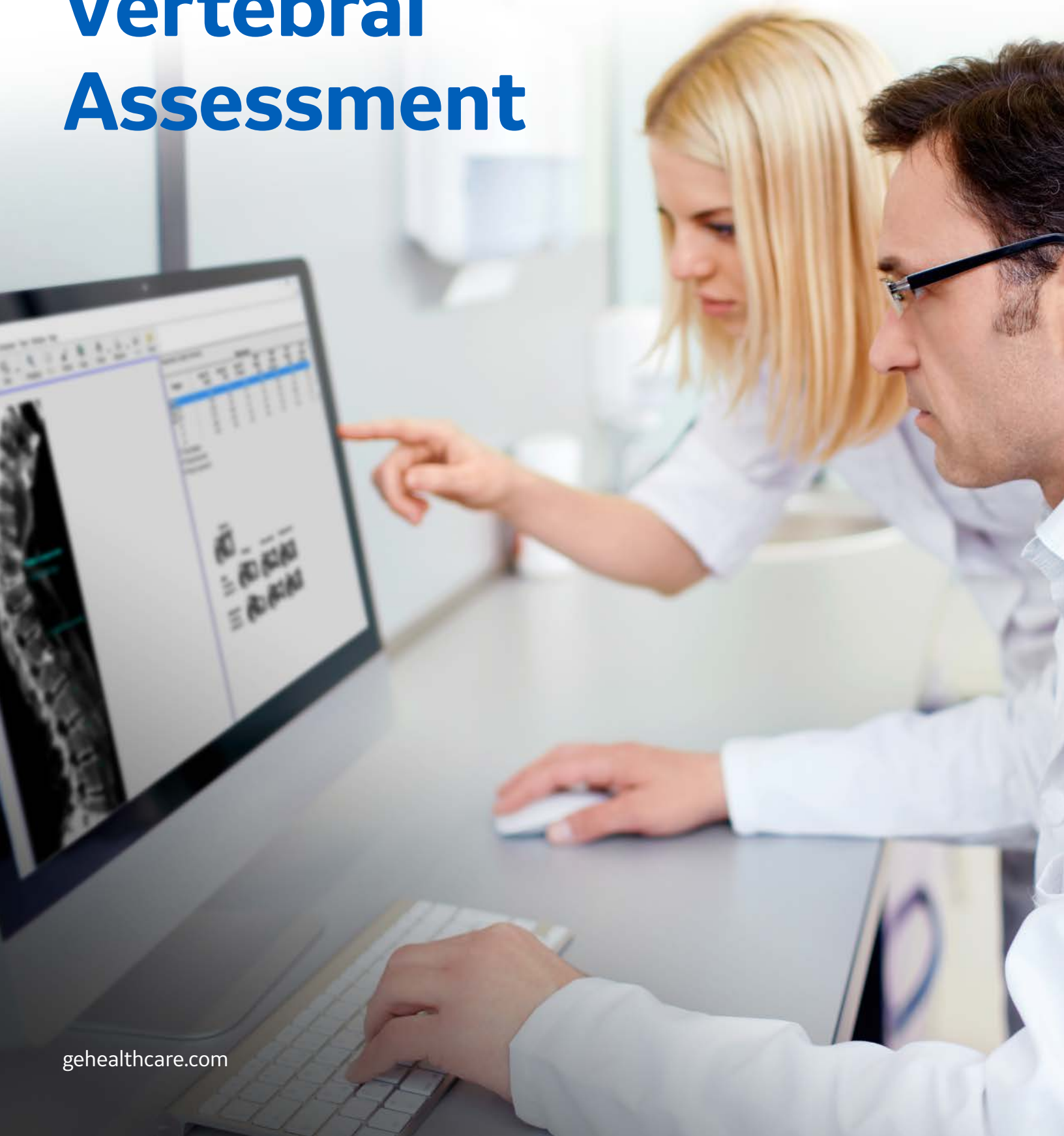



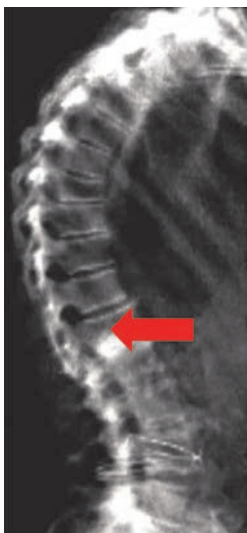# Dual-energy Vertebral Assessment



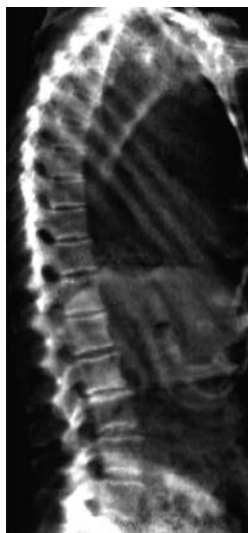
# Dual-energy Vertebral Assessment

Visualize the entire spine (T7-L4) in a single view. Just one fast and easy scan provides both single and dual-energy images.

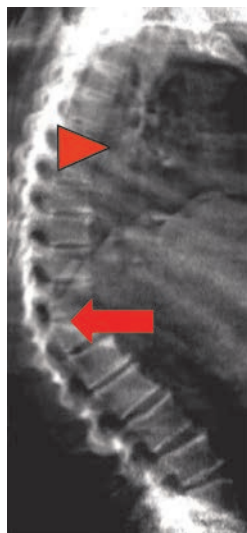
Our exclusive ClearView feature improves bone edge detail and eliminates the need for a centerline scan



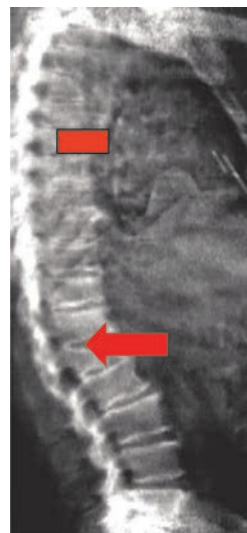**Arthritic Calcification**  
Female, Age 80



**Normal**  
Female, Age 79



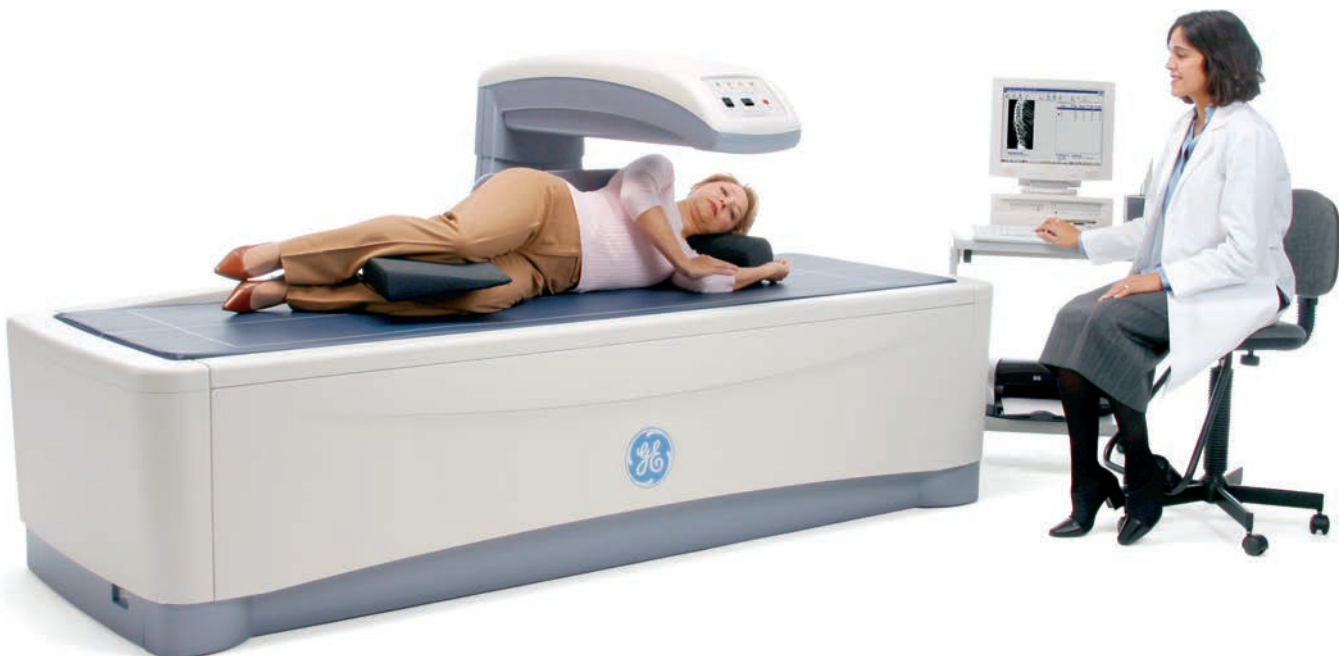**Severe Wedge**  
Female, Age 65



**Severe Compression**  
Female, Age 75

“Severe osteoporosis often presents clinically as a low-trauma fracture of the spine, hip, forearm or ribs. Once an osteoporotic fracture occurs, the risk for subsequent fracture increases dramatically.”<sup>1</sup>

Qualitative assessment visualizes fractures, deformities and artifacts.



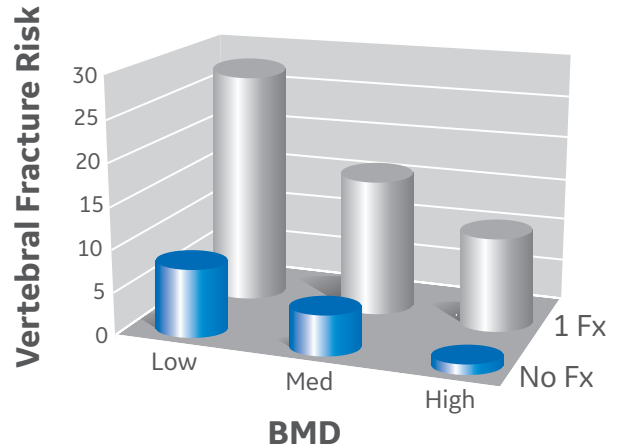
An existing vertebral fracture increases the risk for subsequent vertebral fractures 3 to 10 times, regardless of bone density. Patients with an existing fracture and low BMD (bone mass density) are 25 times more likely to fracture than those with normal BMD and no fracture.<sup>1</sup>

## Identifying vertebral fractures

Knowing whether or not a patient has an existing vertebral fracture can significantly influence that patient's clinical management.

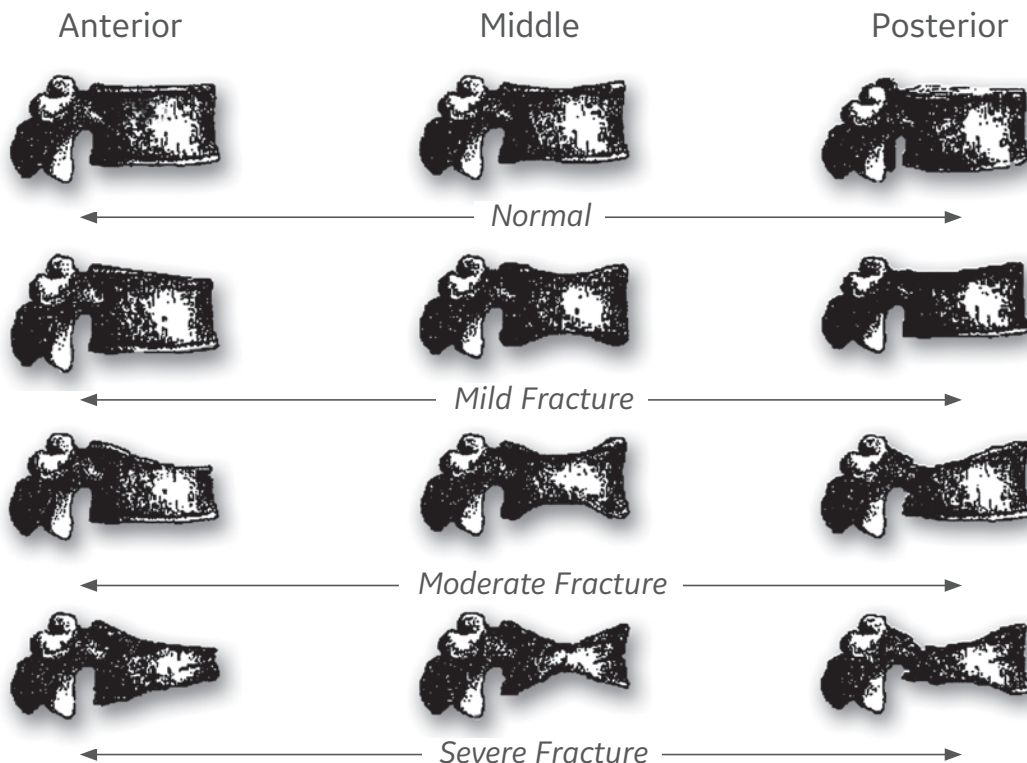
Studies show up to half of all vertebral fractures are never diagnosed. The back pain of a vertebral fracture is often attributed to other causes – and it may not even be severe enough to require a physician visit. As a result, many of these fractures go undetected.<sup>2</sup>

Dual-energy Vertebral Assessment, or DVA, performed on the Prodigy or Lunar iDXA, is an important feature providing a spine image highly useful in the assessment of a patient's fracture status.



Difference in vertebral fracture risk between subjects with and without an existing vertebral fracture (Ross et al, Ann Intern Med 114(11); 919-923, 1991).

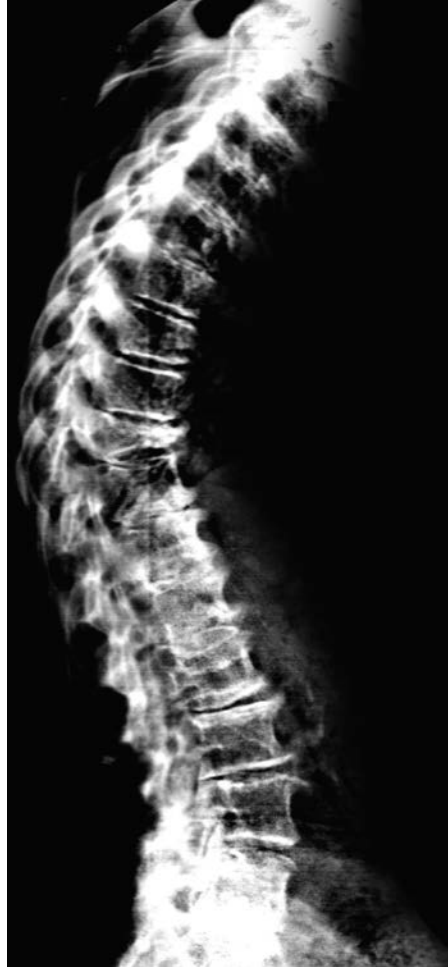## Classifications of Vertebral Fractures<sup>3</sup>



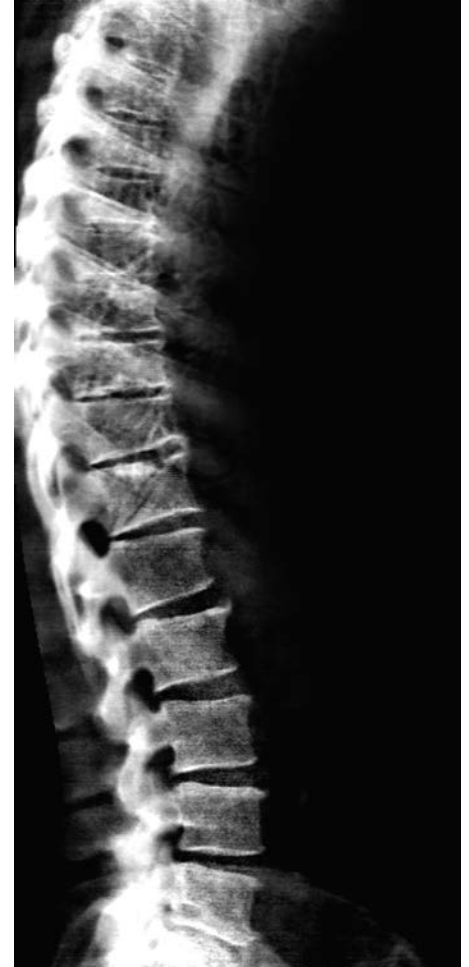# Benefits of DVA

“High-resolution radiographs are the optimal choice for fracture determination, but are not always easily available. We’ve found dual-energy DVA to be a convenient and rapid alternative to spine X-ray. The dual-energy image is easier to read than single-energy scans, and it can be combined with a bone density exam.”

Patrick K. Burke, M.D. Osteoporosis Diagnostic and Treatment Center, Retreat Hospital, Richmond, Virginia



80 year old female, 61 in., 127 lbs.



48 year old male, 67 in., 148 lbs.

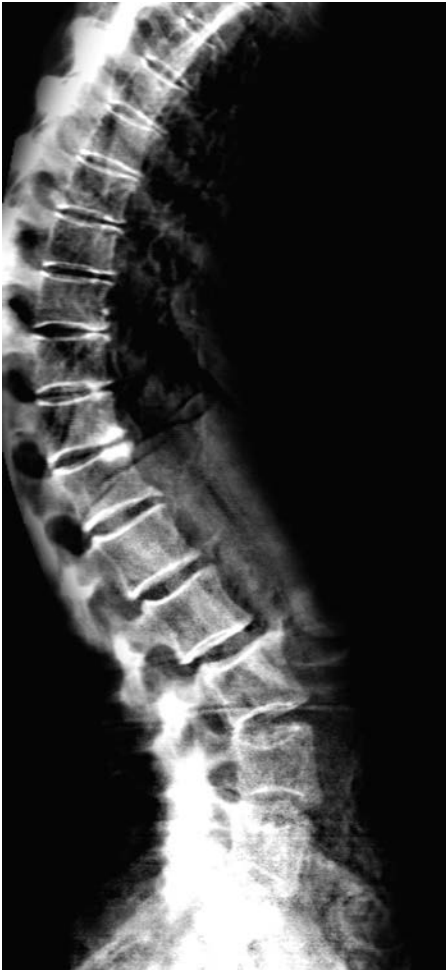## DVA vs. conventional spine radiographs

The conventional spine radiograph is today's standard for vertebral assessment. It provides high-quality image resolution enabling you to visualize more vertebrae, mild fractures and other features.<sup>3</sup>

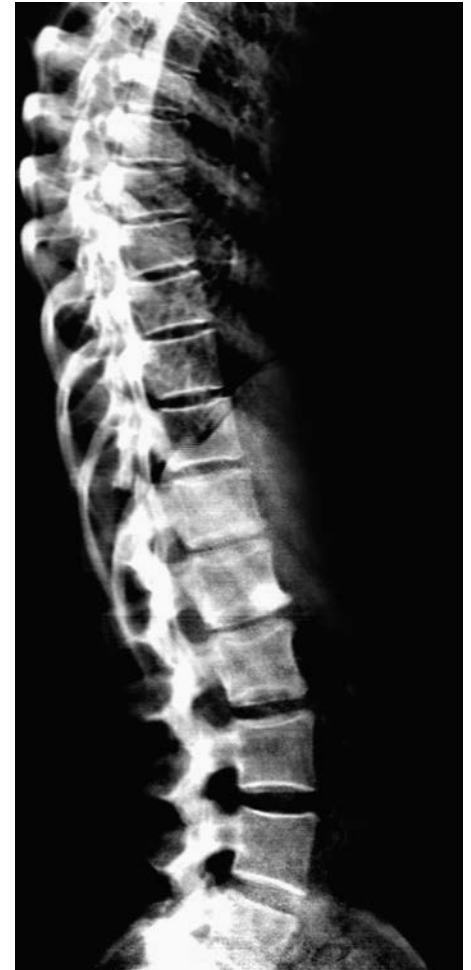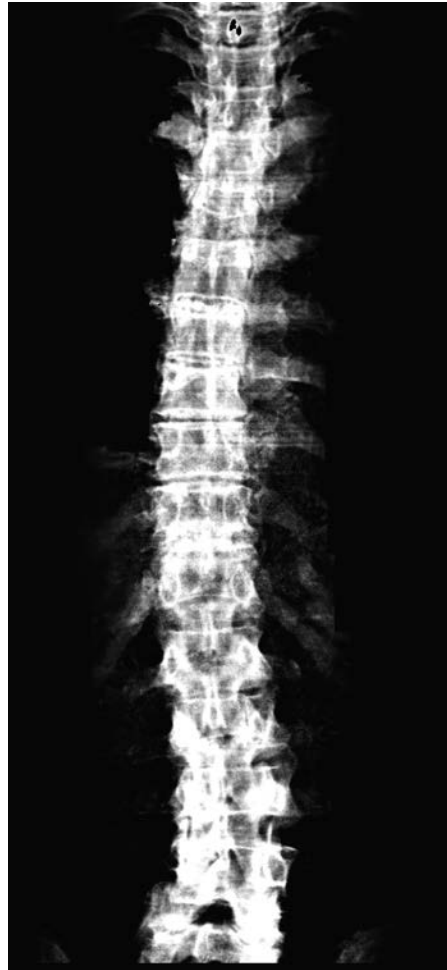However, a DVA performed on the Prodigy series or Lunar iDXA densitometer offers several key advantages in assessing vertebral fractures:

- Low-dose point of care
- Subtract soft tissue with artifacts
- Shows both single- and dual-energy images





77 year old female, 63 in., 117 lbs.



65 year old female, 66 in., 138 lbs.

## A single view of the spine

Conventional radiographs require separate thoracic and lumbar films to adjust for the considerable differences in soft-tissue density between the chest and abdomen.<sup>3</sup> The dual-energy technique utilized by GE Healthcare compensates for these differences to visualize the entire spine (T7-L4) in a single view.

## Two views for enhanced assessment

- The AP view for enhanced visuals of the ribs and pelvis and labeling of vertebral bodies
- The lateral view for visual and quantitative assessment using the morphometry wizard

View either single- or dual-energy images.

Visualize vertebral fractures obtained by the DVA acquisition of both single-energy and dual-energy scans.

## Morphometry

The morphometry wizard automatically labels vertebral deformations by using a six-point measurement of the anterior, posterior and mid-heights of vertebrae.

## ClearView filter

The ClearView filter enhances images to show bone edges better. It is applied only to improve bone edge detail, while reducing noise to soft tissue. The filter is dynamically adjustable, as the operator controls the amount of enhancement with a slide bar for viewing real-time image change.

## Digital acquisition and storage

The fully digital DVA image allows enhanced control for viewing and analysis, and is DICOM<sup>®</sup> compatible for easy electronic storage and access.

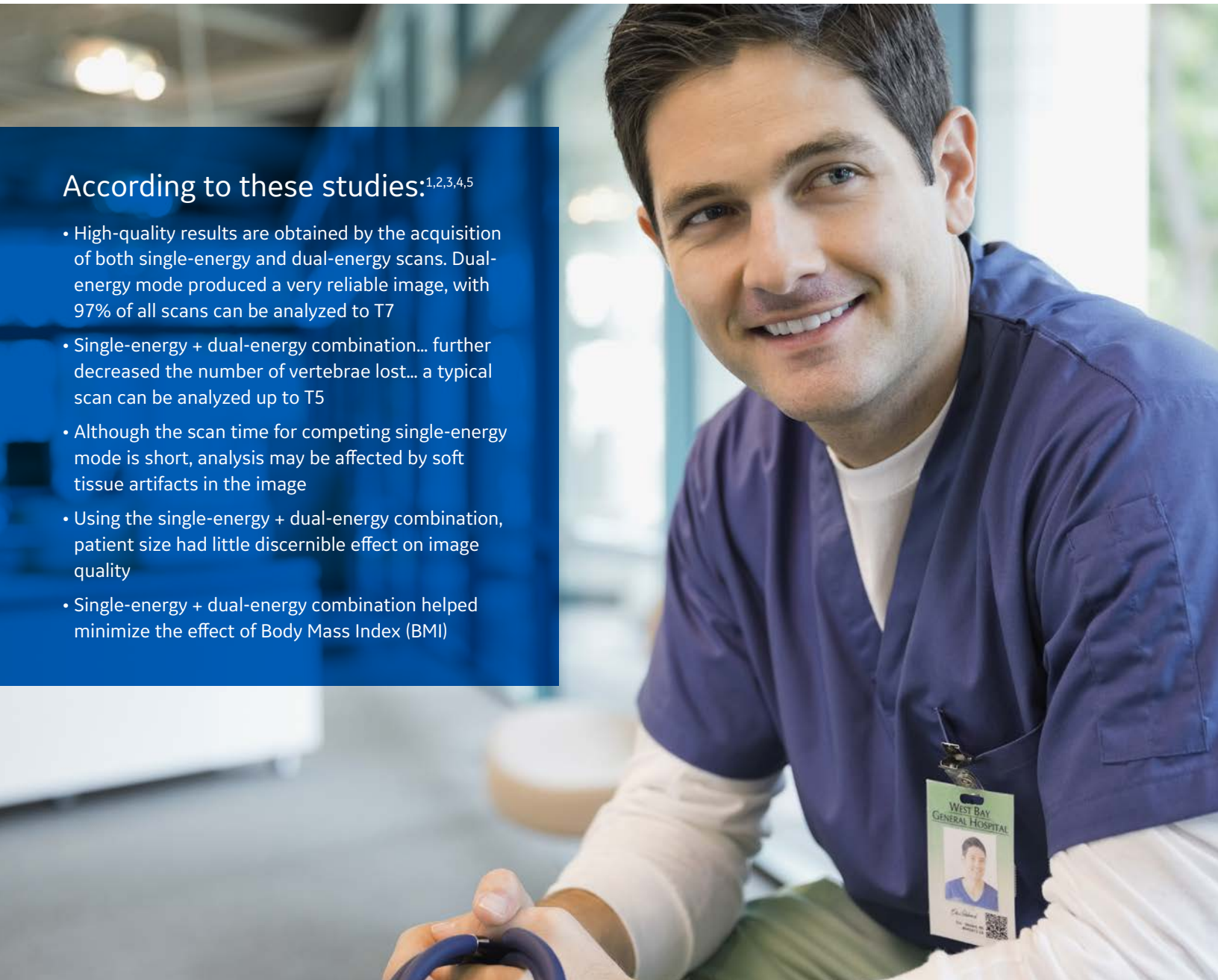
# Vertebral assessment backed by scientific data

## Combined single-energy and dual-energy imaging

Published studies show that combining dual-energy scans with single-energy scans – as provided by GE Healthcare’s DVA in one fast, single-pass acquisition – gives you an exceptional VFA diagnostic tool.<sup>1,2,3,4,5</sup>

### According to these studies:<sup>1,2,3,4,5</sup>

- High-quality results are obtained by the acquisition of both single-energy and dual-energy scans. Dual-energy mode produced a very reliable image, with 97% of all scans can be analyzed to T7
- Single-energy + dual-energy combination... further decreased the number of vertebrae lost... a typical scan can be analyzed up to T5
- Although the scan time for competing single-energy mode is short, analysis may be affected by soft tissue artifacts in the image
- Using the single-energy + dual-energy combination, patient size had little discernible effect on image quality
- Single-energy + dual-energy combination helped minimize the effect of Body Mass Index (BMI)



“The lumbar vertebrae are especially well visualized on single-energy scans, but the increasing effect of soft tissue artifacts as one moves up the thorax can impair visualization of the thoracic vertebrae. The image, therefore, requires more practice and experience to analyze successfully. If time constraints allow, acquisition of both single-energy and dual-energy scans provide the optimal approach.”<sup>5</sup>

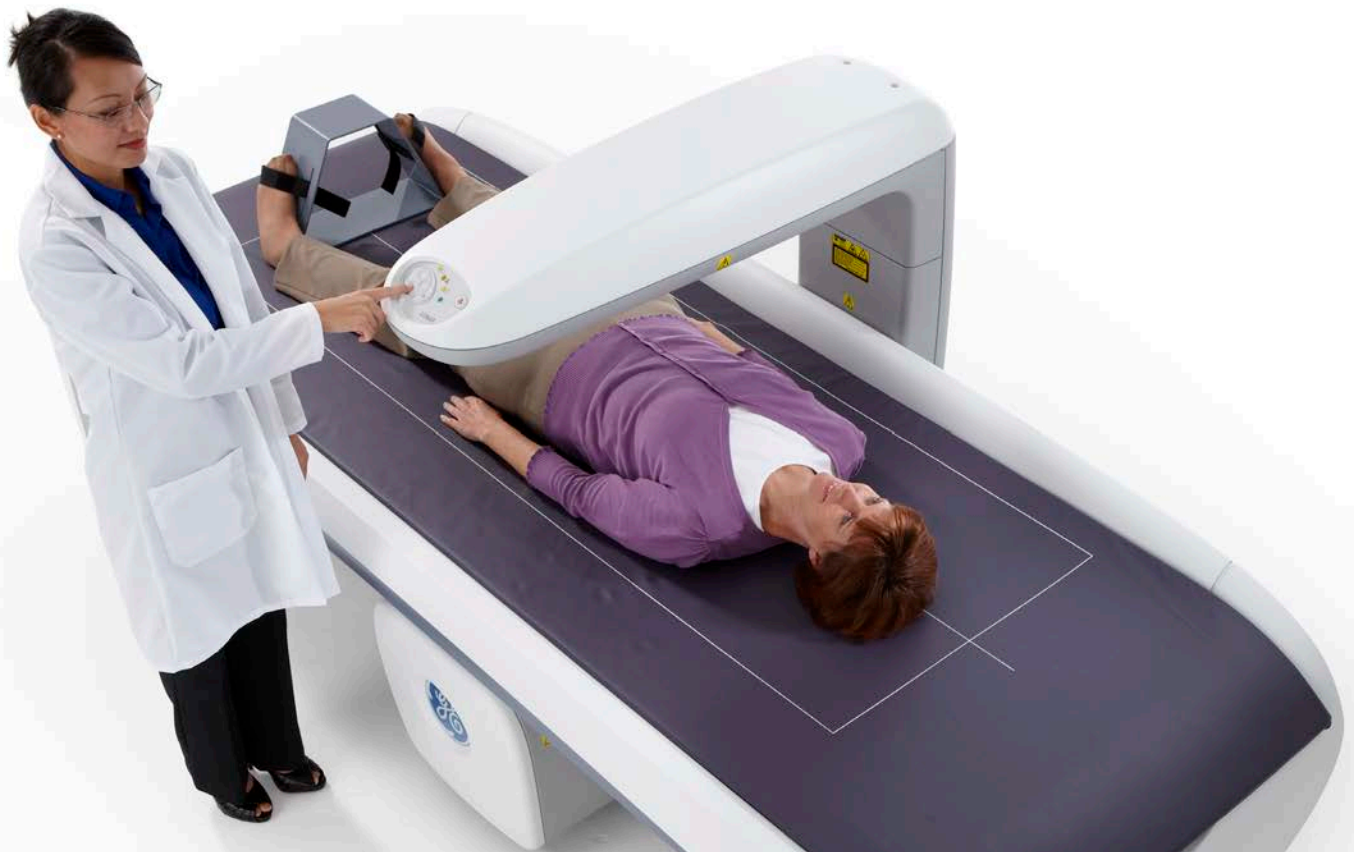One fast and easy 2-minute scan provides both single- and dual-energy images. Exclusive ClearView feature eliminates the need for a centerline scan.



Lunar iDXA



Prodigy



**References:**

1. Ross PD, Davis JW, Epstein RS, Wasnich RD, 1991 Pre-existing fractures and bone mass predict vertebral fracture incidence in women. *Ann Intern Med* 114 (11):919-923.
2. Melton LJ III, Lane AW, Cooper C, Eastell R, O'Fallon WM, Riggs BL, 1993 Prevalence and incidence of vertebral fractures. *Osteoporosis Int* 3:113-119.
3. Genant et al, *Journal of Bone Mineral Research* 2003
4. Rea JA, Li J, Blake GM, Steiger P, Genant HK, Fogelman I, 2000 Visual Assessment of vertebral deformity by X-ray absorptiometry: a highly predictive method to exclude vertebral deformity. *Osteoporosis Int* 11:660-668.
5. Rea JA, Steiger P, Blake BM, Fogelman I, 1998 *Osteoporosis Int.* 8:177-183.



© 2022 General Electric Company – All rights reserved.

GE Healthcare reserves the right to make changes in specifications and features shown herein, or discontinue the product described at any time without notice or obligation. Contact your GE Healthcare representative for the most current information. GE, the GE Monogram, imagination at work, Prodigy and Lunar iDXA are trademarks of General Electric Company. DICOM is a registered trademark of National Electric Manufacturers Association (NEMA). GE Healthcare, a division of General Electric Company. GE Medical Systems, Inc., doing business as GE Healthcare.