



## SIGNA™ ARTIST


30ch Air-Coil imaging of Osteomyelitis in a very painful and swollen right lower leg.

Addenbrooke's Hospital Cambridge UK

Simon F Dezonie

UK Clinical Zone Leader

14/10/2020



**Clinical History:**

33 years old Male patient presenting with right tibial osteomyelitis with inflammatory phlegmon. The right leg had become very painful and swollen.

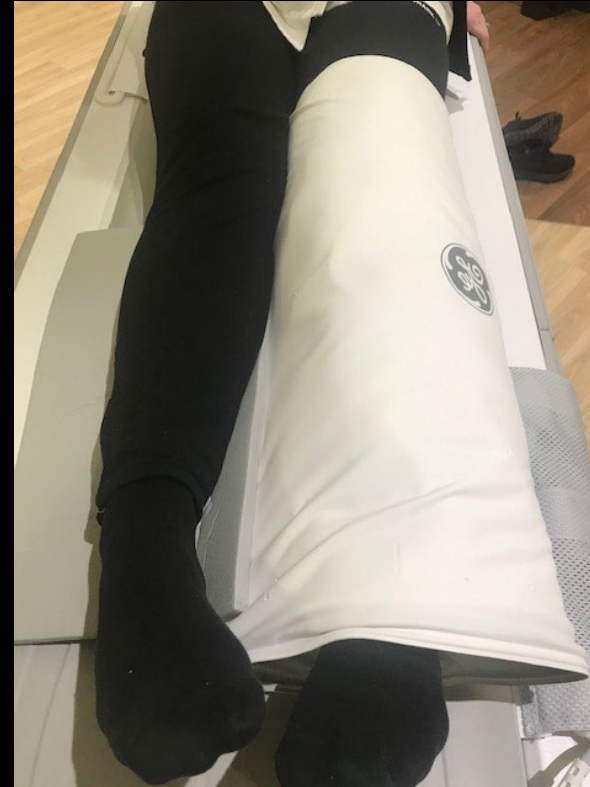?fluid component adjacent to the inflammatory mass. ? worsening infection.

**MRI Sequences:**

Coronal T1 FSE , Coronal T2 Fat Sat FRFSE, Axial STIR FSE ,Axial T1 FSE, Axial T1 FSE & Fat Sat (post gadolinium), & Coronal T1 FSE & Fat Sat

**Clinical Findings:**

Fluid within the intra medullary cavity extending into the cortical tracts. There is also bone oedema. The appearance would be in keeping with on going osteomyelitis



Volunteer showing Aircoil wrapped around a leg

Feedback from Mrs Claire Goldsmith senior mri radiographer at Addenbrooke's Hospital Cambridge UK

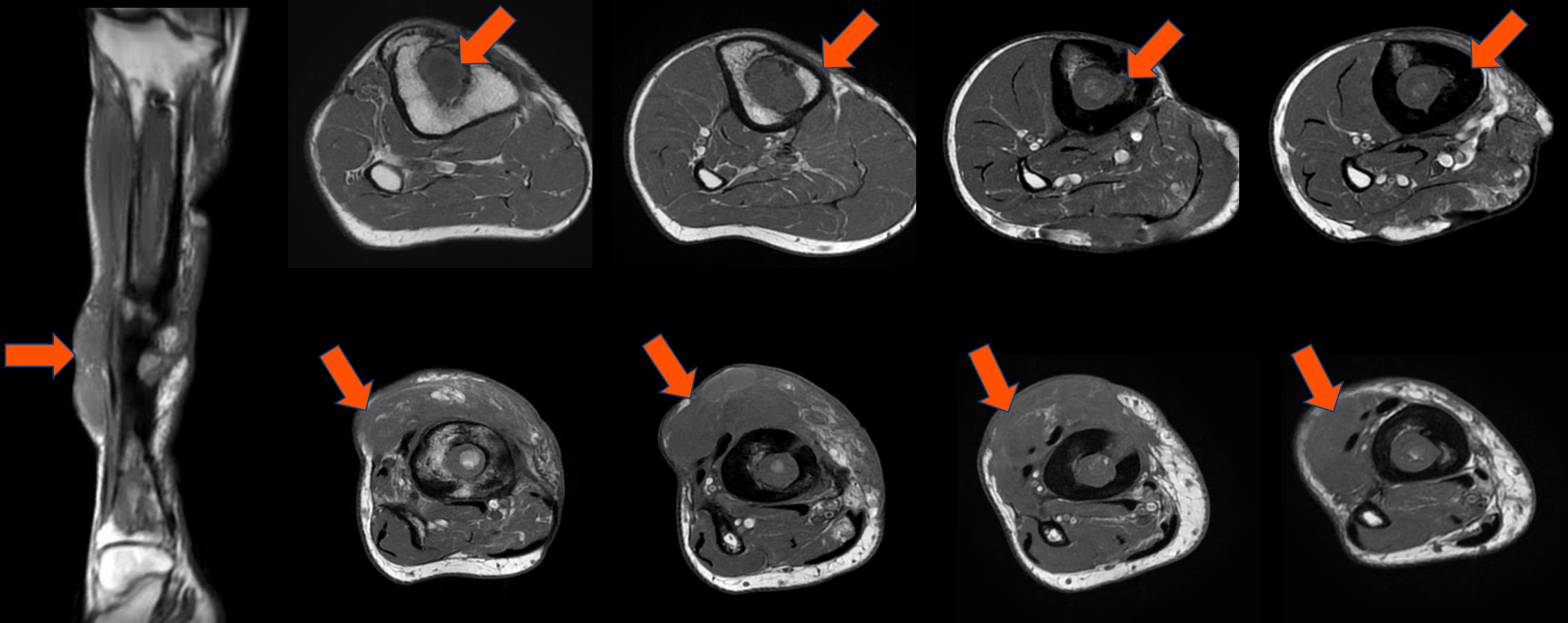
Aircoil was the perfect coil for this patient:

1. I was able to wrap the coil around the patient's swollen leg.
2. Even, though the patient was in pain, he found the coil very comfortable.
3. I was able to scan the whole leg with one coil.



Coronal T1 FSE  
Voxel Size 1.15x1.66x5.0

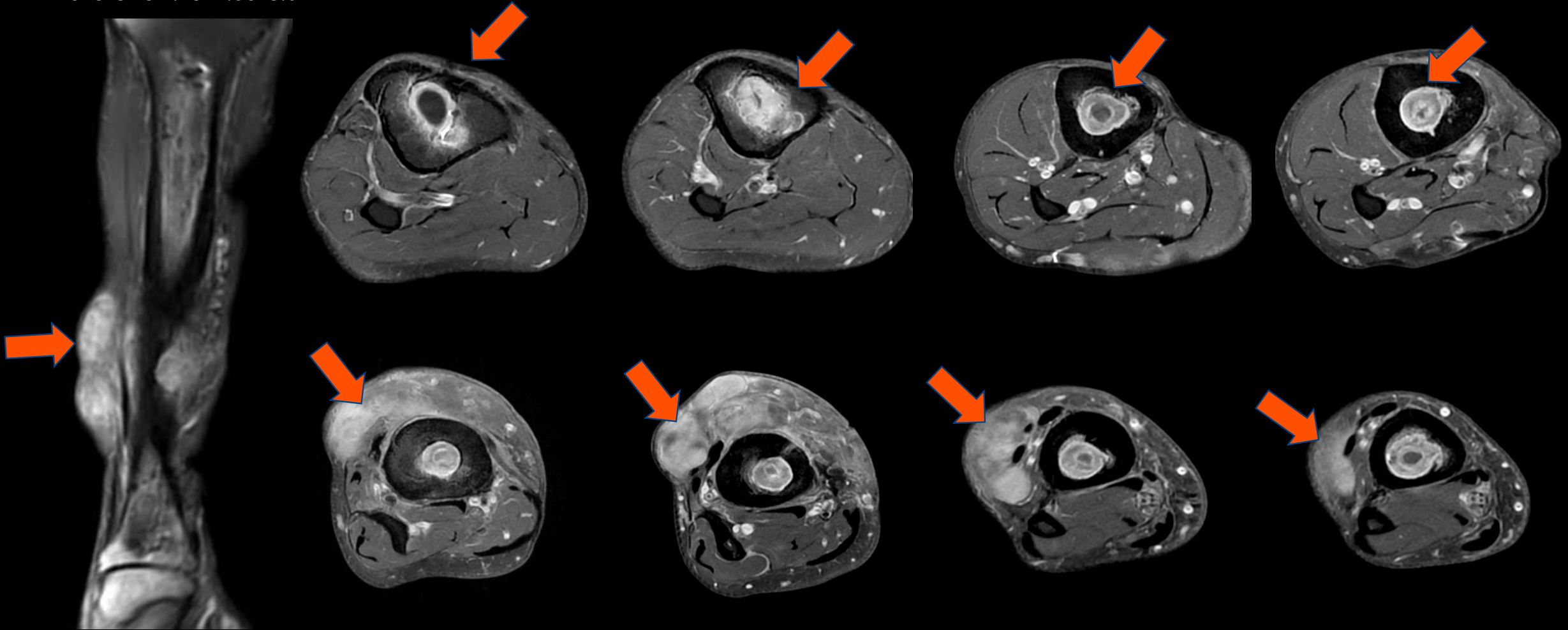
Axial T1 FSE  
Voxel Size 0.5x0.55x5.0



TOMORROW TODAY

Coronal T1 FSE & Fat Sat  
(post gadolinium)  
Voxel Size 1.15x1.66x5.0

Axial T1 FSE & Fat Sat  
(Post Gadolinium)  
Voxel Size 0.5x0.55x5.0



TOMORROW TODAY

Coronal T2 FRFSE Fat & Sat  
Voxel Size 1.44x1.87x5.0

Axial Stir FSE  
Voxel Size 0.83x1.0x5.0

