



Improved Diagnostic Accuracy of Stress Echocardiography Utilizing GE AFI Stress Echo Protocol

Case Study

—

Salima Qamruddin MD, MPH, FASE
Director Women's Cardiovascular Clinic
Ochsner Heart and Vascular Institute
New Orleans, LA

vivid

gehealthcare.com

Introduction

Despite excellent specificity of stress echocardiography, 22% to 33% of patients have been reported to have false-positive results^{1,3,6} (i.e., they are found to have no significant coronary artery stenosis on the subsequent angiogram). Causes of false positive stress tests include hypertensive response to exercise, microvascular abnormalities, endothelial dysfunction and/or small vessel coronary artery disease.² False-positive results can result in invasive, potentially costly diagnostic modalities like coronary angiography.³

Evaluation of baseline Global Longitudinal Strain (GLS) of the left ventricle (LV) has been shown to have 77% sensitivity and 83% specificity to detect significant Coronary Artery Disease (CAD), defined as $\geq 50\%$ diameter stenosis of the affected vessel, in patients undergoing Dobutamine Stress Echocardiography (DSE), and its addition can reduce false positive studies by 83%.³

However, an increase in afterload has been shown to decrease LV GLS, leading to misinterpretation of the true contractile function of the myocardium. The global myocardial work index (GWI), derived using LV pressure-strain loops (Figure 1A), accounts for deformation as well as afterload through interpretation of strain in relation to dynamic noninvasive LV systolic pressure. A recent study shows baseline GWI at rest to be a more sensitive index than GLS to detect significant CAD in patients referred for coronary angiography.⁴ Assuming normal systolic pressure (120 mmHg) and normal global longitudinal strain (-20%), myocardial work will be approximately 2400 mmHg% (Figure 1B) with all the segments contracting during systole, but can be reduced in ischemia (Figure 1C). Myocardial work is evaluated from Mitral Valve Closure (MVC) to Mitral Valve Opening (MVO), in other words the mechanical systole including isovolumetric relaxation (IVR).

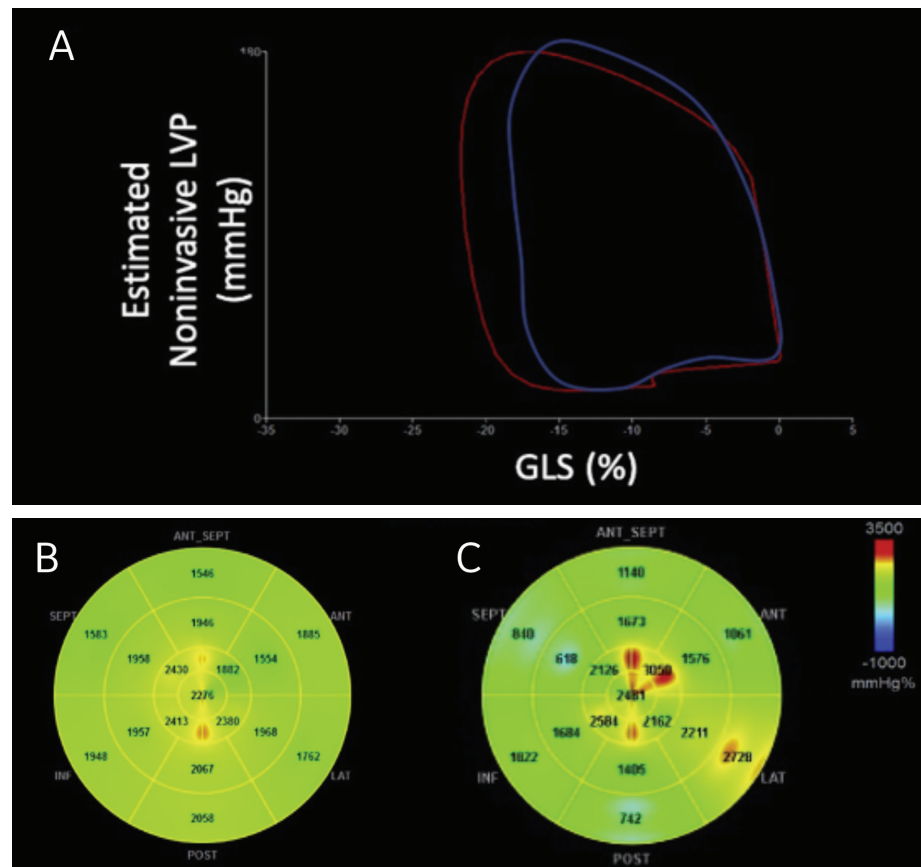


Figure 1A, B and C. Non-invasive LV pressure-strain loop diagram in a patient with no CAD (red) and one with multivessel CAD (blue). Note the overall reduced area under the curve due to lower peak strain values in patient with multivessel CAD despite similar blood pressure. Example of bull's-eye map of myocardial work in a healthy patient (B) and one with multivessel CAD (C). Note the lower segmental strain in (blue areas) in CAD patient.

GE AFI stress Protocol

GE AFI stress protocol can evaluate LV GLS and myocardial work at baseline and peak stress echocardiography (at high heart rates) by incorporating an apical long axis image in the stress protocol at each stage of echocardiography. This results in an average GLS at each stage (Figure 2A).⁵ The bull's-eye map of the GLS can be displayed with strain curves or moving 2D images, so each segment strain can be further evaluated (Figure 2B).

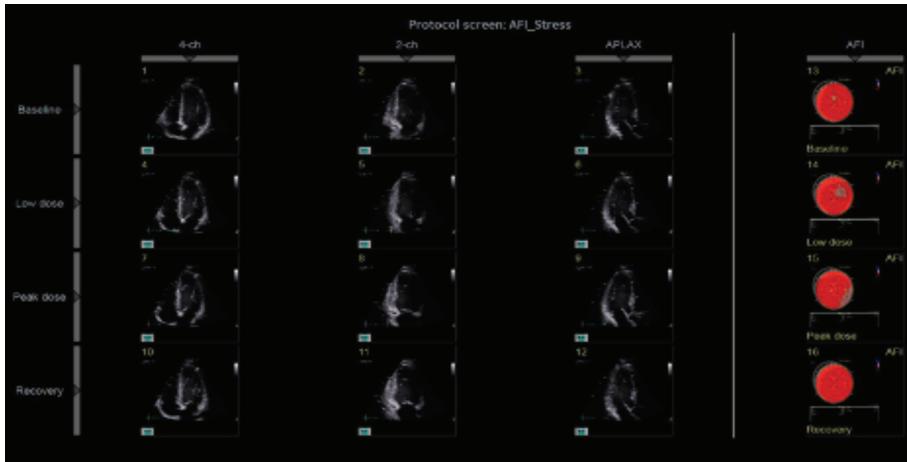


Figure 2A. Average LV GLS (bull's-eye map) segment at each dose of DSE can be seen with strain curves or moving 2D images.*

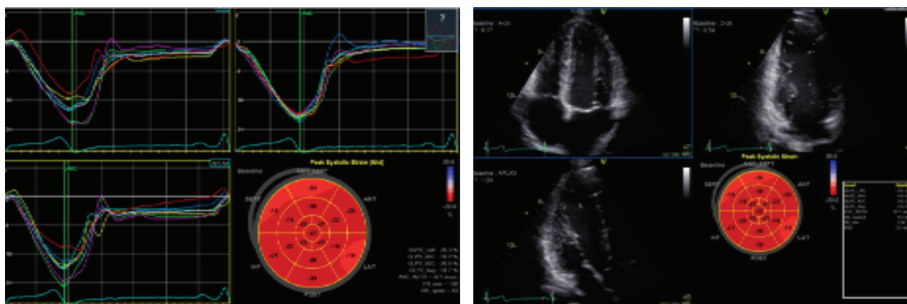


Figure 2B. Bull's-eye map of the GLS can be displayed with strain curves or moving 2D images so each segment strain can be further evaluated at each stage of stress echocardiography.*

Additional steps include marking MVO and MVC and adding systolic blood pressure at each stage. This will show myocardial work and myocardial efficacy map. Myocardial efficiency is calculated by dividing constructive work (work performed by a segment during shortening in systole, adding negative work during lengthening in IVR) divided by the sum of constructive and wasted work (negative work performed by a segment during lengthening in systole, adding work performed during shortening in IVR) and is expressed as a percentage.

*Images used with permission

Cases

Case 1 includes a 51-year-old woman and a 79-year-old man, both with risk factors for CAD who underwent DSE. In the female patient, the distal left anterior descending (LAD) artery territory was hypokinetic. In the male patient, the right coronary artery (RCA) territory was found to be hypokinetic. However, in both patients downstream GLS analysis showed preserved global strain at peak stress (-18% and -17%, respectively) compared to baseline (-18% and -19%, respectively), as well as preserved segmental strain values at peak stress in the territory that was identified ischemic (Figure 3). The secondary positron emission tomography (PET) and single-photon emission computerized tomography (SPECT) respectively did not show any perfusion abnormality and were negative for ischemia.

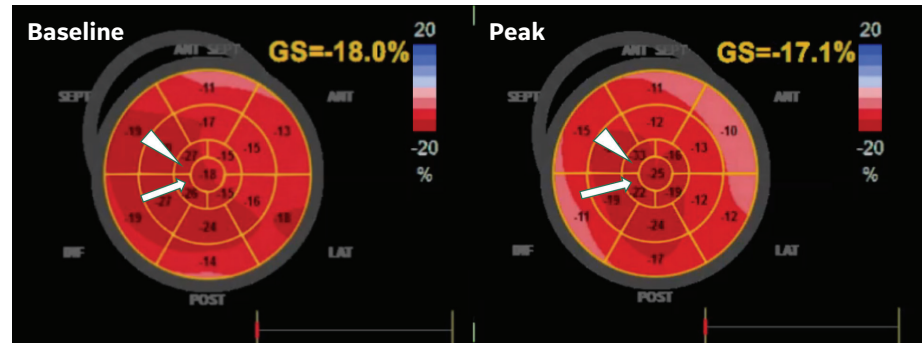


Figure 3. LV GLS at baseline and peak stress in patient with false-positive DSE in the LAD territory. Note preserved segmental strain in apical septal and apical inferior segment at peak stress compared to baseline (arrow and arrowhead).

Case 2 is about a 56-year-old woman with chest pain and risk factors for CAD who had a hypertensive response (Peak BP 211/100 mmHg) during DSE. The initial study was considered positive for myocardial ischemia in the apical septal and apical inferior, but subsequent analysis incorporating peak GLS and GWI revealed that even though the GLS decreased from baseline to peak (-12 vs. -10%), GWI (954 vs. 1113 mmHg%) and global constructive work (GCW) (1209 vs. 1952 mmHg%) increased at peak constructive myocardial work, suggesting increased overall myocardial work and arguing against ischemia (Figure 4). Also, segmental myocardial work is preserved (Figure 4), and subsequent cardiac catheterization showed non obstructive CAD.

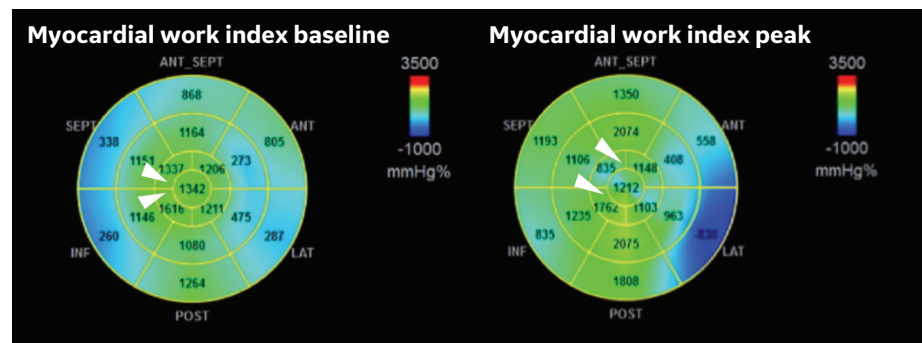


Figure 4. Increase in myocardial work index (954 vs. 1113 mmHg%) with preserved myocardial work values in the apical septal and apical inferior wall (green color map that are normal values) in a patient with false positive DSE due to severe hypertension.

VARIABLES	BASELINE	PEAK STRESS
Blood Pressure (mmHg)	103/76	211/100
GLS (%)	-10	-12
Global Myocardial Work (mmHg%)	954	1113
Global Constructive Work (mmHg%)	1209	1952
Global Work Efficiency (%)	85	79

Table 1. Systolic blood pressure, myocardial work and efficiency at baseline and at peak stress in patient with false positive DSE due to severe hypertension.

Case 3 is a 58-year-old woman with CAD risk factors and cirrhosis who underwent DSE to evaluate persisting hypoxemia. The 2D evaluation was interpreted as positive in the LAD territory and concurrent GLS analysis showed a decrease from -19% to -15% with segmental drop in strain in apical septum and apical cap (Figure 5A), with a concurrent myocardial work change from 2348 mmHg% to 907 mmHg% (Figure 5B). This was subsequently confirmed with angiographic findings of a long LAD lesion.

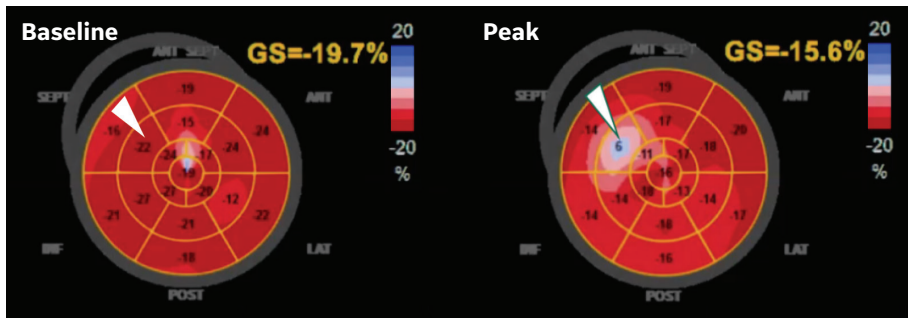


Figure 5A. Segmental strain drop in apical septum (from -22% to -6%) (arrowhead), with overall decrease in GLS that suggests ischemia in the distal LAD as confirmed by cardiac catheterization.

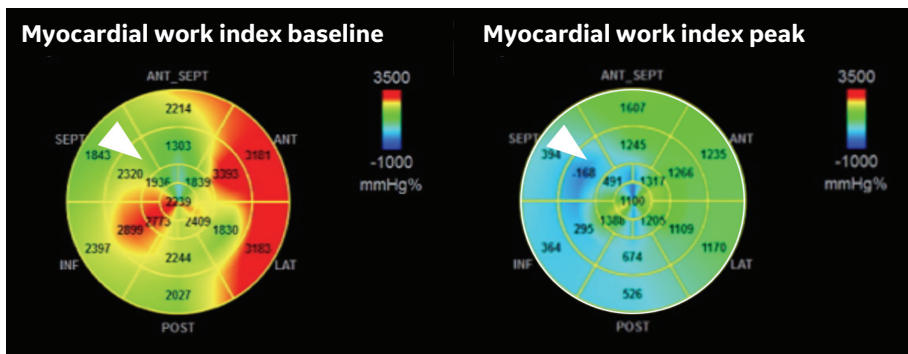


Figure 5B. Severe decrease in myocardial work in the septum, distal inferior wall and apex (change of color from green (normal) to blue (decrease)) due to ischemia in the LAD territory.



Conclusion

- ▶ Incorporating GLS and myocardial work in stress echo has the potential to **significantly improve the accuracy** of this testing modality
- ▶ Employing GLS and myocardial work in stress echo in the three false-positive patients in this case study **reduced an average cost of \$5,300/patient** for subsequent SPECT/PET/angiographic evaluation*
- ▶ Therefore, reducing the number of false-positive stress tests will **maximize value** in fixed payment models by avoiding costly SPECT/PET/angiographic evaluations

**Costs identified relate to the three shown cases in this study and may not be representative of costs for other cases or at other facilities*



References

- ¹Pellikka PA, Nagueh SF, Elhendy AA, Kuehl CA, Sawada SG; American Society of Echocardiography. American Society of Echocardiography recommendations for performance, interpretation, and application of stress echocardiography. *J Am Soc Echocardiogr.* 2007 Sep; 20(9):1021-1041
- ²Labovitz AJ. The “myth” of the false positive stress echo. *J Am Soc Echocardiogr.* 2010 Feb;23(2):215-216.
- ³Roushdy A, Abou El Seoud Y, Abd Elrahman M, Wadea B, Eletriby A, Abd El Salam Z. The additional utility of two-dimensional strain in detection of coronary artery disease presence and localization in patients undergoing dobutamine stress echocardiogram. *Echocardiography.* 2017 Jul;34(7):1010-1019.
- ⁴Global Myocardial Work Is Superior to Global Longitudinal Strain to Predict Significant Coronary Artery Disease in Patients With Normal Left Ventricular Function and Wall Motion. Edwards NFA, Scalia GM, Shiino K, Sabapathy S, Anderson B, Chamberlain R, Khandheria BK, Chan J. *J Am Soc Echocardiogr.* 2019 Aug;32(8):947-957. doi: 10.1016/j.echo.2019.02.014. Epub 2019 Apr 28.
- ⁵Evaluation of segmental myocardial work in the left ventricle.
<https://apps.gehealthcare.com/-/media/b60b18acef594167a79e023a831cd913.pdf?la=en&rev=4ca9e619177d44ab9e7c1c931a0a6225>
- ⁶AM, Kane G, Bruce C, Pellikka PA, Scott C, McCully RB. Characteristics and outcomes of patients with abnormal stress echocardiograms and angiographically mild coronary artery disease (<50% stenoses) or normal coronary arteries. *J Am Soc Echocardiogr.* 2010 Feb;23(2):207-14. doi: 10.1016/j.echo.2009.11.023. PMID: 20152703.