

# ViewPoint 6

GE Healthcare

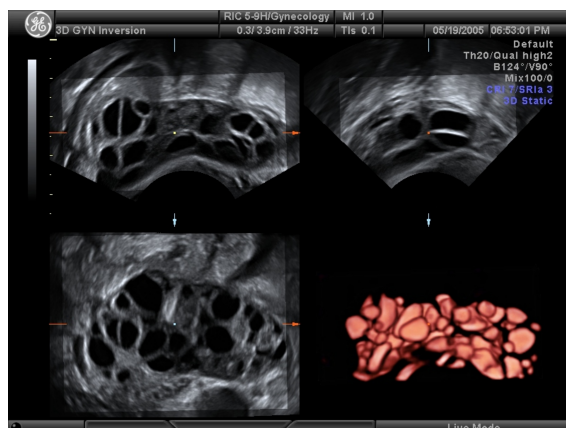
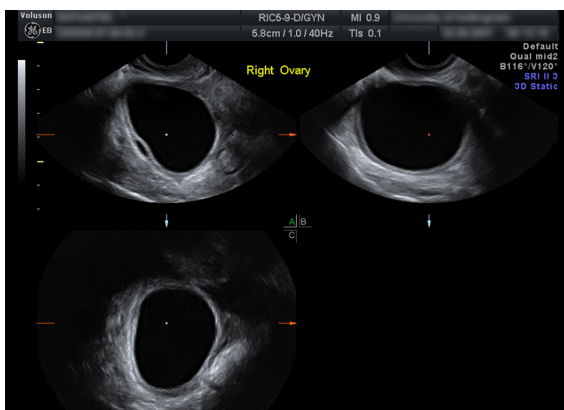


Susan L. Pelvic  
43532 Sunseeker Ave.  
Los Angeles CA 90011

Date: 11/26/2010

## Pelvic Ultrasound Examination

- Indication** Suspected ovarian cyst.
- Method** Transvaginal ultrasound examination. Good view.
- Uterus** Abnormal. Position: anteverted. Long/AP/Tr. 6.0 cm x 4.0 cm x 5.0 cm. Vol. 62.8 cm<sup>3</sup>. Endometrial thickness single layer: 1.0 mm.  
Fibroid(s) Multiple fibroids within the myometrium identified.
- Right Ovary** Abnormal. Size 6.5 cm x 5.6 cm x 4.9 cm. Mean 5.7 cm.  
Cyst(s) Simple cyst. Size 3.0 mm x 3.5 mm x 2.9 mm. Mean 3.1 mm.
- Left Ovary** Abnormal. Morphology: polycystic. Size 5.0 cm x 3.4 cm x 3.8 cm. Mean 4.1 cm.  
Cysts identified.
- Cul de Sac** Free fluid visualized (mild).  
Largest pool 20.0 mm.
- Bladder** visualized, WNL
- .
- Impression** Anteverted uterus seen with abnormal bilateral ovaries.  
Right ovarian simple cyst seen.  
Left ovary has multiple simple cysts throughout.
- Follow-up** A repeat evaluation is recommended in one month.



B. Miller  
Sonographer

Dr. B. Winter  
Performing physician