



## Pursuing an MR-only approach to radiation therapy planning

For over a decade, the University Hospital of Umeå has been using MR for radiation therapy (RT) planning. MR imaging is a useful adjunct to CT because of its ability to depict soft tissue anatomy. The clinical impact is most established for cervical cancer. In fact, the European Society for Radiotherapy & Oncology (ESTRO) released new guidelines in 2012 for the use of MR in volumetric treatment planning in cervical cancer brachytherapy.<sup>1</sup>

According to Professor Tufve Nyholm, PhD, Department Head, Radiation Physics, Oncology at Umeå University, MR is used at the institution in treatment planning for nearly all cancers across different therapy regimens—external beam RT (EBRT), brachytherapy and proton therapy. A standalone CT is still acquired for density information on each patient for use in dose calculations. “The target is defined by MR imaging,” Professor Nyholm says. Umeå was one of the first institutions worldwide to install the SIGNA™ PET/MR in January 2015.

Because of the value of MR for lesion visualization and delineation, Umeå has transitioned a majority of treatment planning cases to SIGNA PET/MR. The exception are suspected lung tumors and head and neck cases where PET/CT is used in the diagnostic workup and therefore, also utilized for RT planning.

Depending on the body part, either T1-weighted or T2-weighted images provide a good depiction of the patient’s anatomy, Professor Nyholm explains. Then, to define the volume of the pathology, T2-weighted images are used for cancers of the pelvic region and contrast-enhanced T1-weighted images are preferred for brain cancers.

---

**“The main difference between diagnostic and therapy planning with PET/MR is we tend to use more 3D imaging in RT. We also use much longer acquisition times in the bed position where the tumor is located.”**

---

*Professor Tufve Nyholm*

Umeå has modified its MR protocols with respect to contrast, minimal slice thickness and adequately high bandwidth to enhance visualization and reliability of where the tumor starts and stops—critical information in treatment planning. Umeå strives to utilize a maximum slice thickness of 2.5 mm without slice gap and 3D isotropic sequences such as Cube are used when possible. Diffusion is another common sequence Umeå uses. In many cases, there is a need for both PET and MR imaging data.

---

**“It is a big advantage to acquire PET and MR data simultaneously for clinical decision making. Then we have the same coordinates in the data and avoid registration problems when fusing the data.”**

---

*Professor Tufve Nyholm*

Typically, the patient is scanned for 25-30 minutes in one bed position on the PET/MR. The goal is to acquire as much information on the target area as possible. Patients referred to RT have already received a diagnostic workup and are identified with localized, not metastatic, disease.

“We know the area to treat so there is no need to image the rest of the body with another bed position,” he adds. “We want to acquire as much information as possible to define the volume for treatment. Even a millimeter in one direction is important for the patient’s plan—in these instances more is better.”

Professor Nyholm also points out that it is well known that most Treatment Planning Systems (TPS) are not optimized for MR imaging—they are simply not designed to handle the volume of data that MR

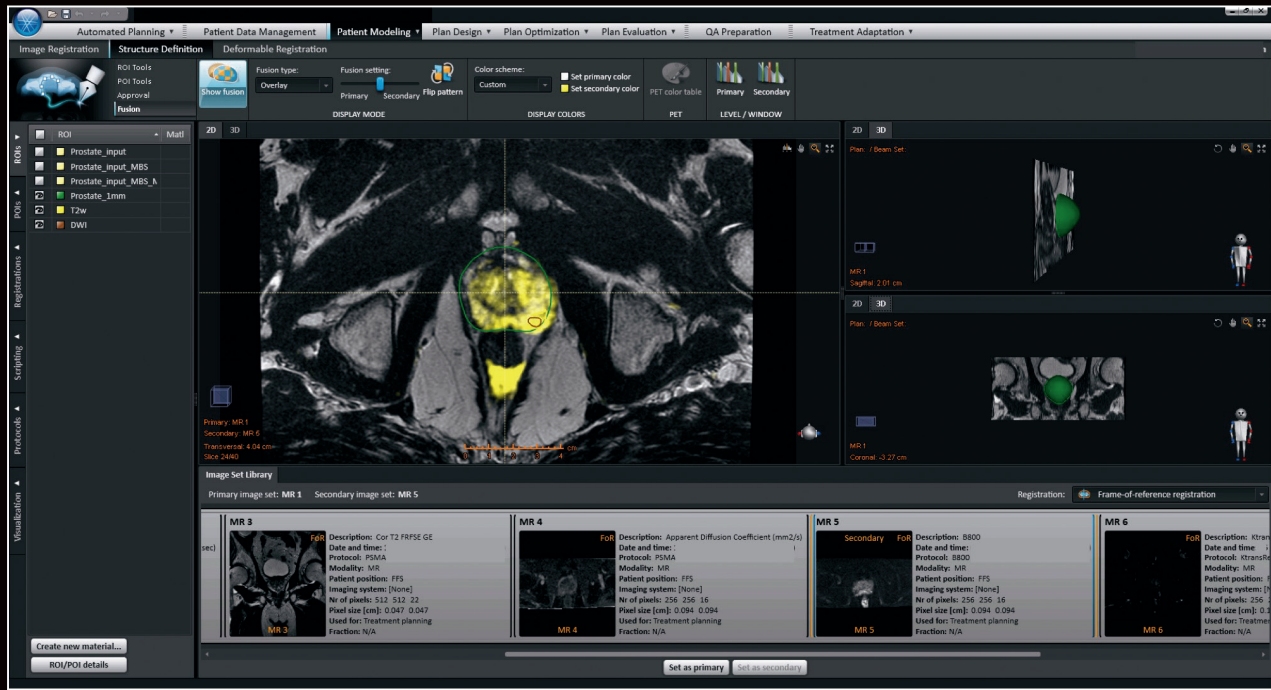


Figure 1. Patient MR images in a treatment planning system, demonstrating an overlay of diffusion b800 on a T2w MR image. The patient was imaged with PET/MR and PSMA-tracer and the delineated subvolume within the prostate represents the PSMA uptake. Umeå is in the validation phase for planning radiotherapy based on PSMA.

imaging generates. While this can be problematic, Umeå has addressed this issue by providing only the key images in the TPS while making the remaining MR imaging data available for review in PACS.

“The underlying problem is that the MR vendors see the need to adapt to RT,” Professor Nyholm says. “But the way I see it, the right thing is for RT to adapt to MR.”

### Impact of MR images in RT

Radiation therapy is radiotoxic to normal, healthy tissue. Gains in curative and survival rates along with enhanced quality of life for cancer patients have largely been attributed to advancements in treatment delivery systems, such as multi-leaf collimators, Intensity Modulated RT (IMRT) and

Volumetric Modulated Arc Therapy (VMAT). The accuracy of treatment delivery is enabled by the clarity and precision of modern medical imaging such as CT and MR. These imaging modalities provide the detailed information physicists and oncologists need to treat only the cancerous lesion and avoid healthy tissue.

At Umeå, Professor Nyholm and his colleagues see the impact of MR imaging in treatment planning because they can clearly visualize the lesion and surrounding healthy tissue.

“We have not yet reduced margins but we have seen a change in the volumes we are treating,” he explains. “In prostate cancer, we have reduced target volumes by using MR imaging.”

Head and neck cancer is another area where MR has made a significant impact. Images from patients with implants or fillings in their teeth result in significant artifacts in CT.

“With MR, we can suppress these artifacts and obtain good image quality. Obviously, in patients with brain tumors MR is preferred. Even in an ideal case we often can’t get the information we need with CT.”

### Addressing prior challenges to using MR in RT

Acquiring images for planning with the patient in the treatment position is important for the accuracy of the plan. Historically, this has been an issue with the use of MR in RT. However, the development of wider bores and smaller, more flexible coils has helped to diminish this challenge.

Umeå has been working with GE Healthcare to develop the infrastructure needed to acquire patient images in the right position. However, Professor Nyholm believes other options exist, as well.

**“One idea is to explore the possibility to treat the patient in the imaging position rather than image them in the treatment position. If this is possible, then we won’t have this problem. It seems to be the obvious thing to do.”**

*Professor Tufve Nyholm*

Geometric inaccuracies are another area that have historically been a concern when using MR for RT. MR distortions can be caused by gradient field nonlinearity, which can impact PET attenuation correction.

Professor Nyholm believes that if the physicist has a knowledge of MR imaging and potential issues, they can avoid this issue. He is a co-author of a published paper that concluded when using a well-adjusted sequence bandwidth, the distortions caused by patient susceptibility effects can be kept at an acceptable level.<sup>2</sup> It has already been verified in several publications that when using 3D distortion correction the small remaining distortions have a minimal effect on the quality of the treatment.

Umeå is also involved in a collaboration between academic institutions in Sweden and industry leaders, including GE Healthcare. The focus of the consortium, Gentle Radiotherapy, is to develop MR-only RT. Professor Nyholm shares that Umeå is responsible for developing the methodology for MR-based RT in the pelvis, e.g., bladder, cervix and anal cancer, excluding prostate. The consortium already has a joint publication on MR-only treatment planning for prostate.<sup>3</sup>

“The biggest challenge is education,” Professor Nyholm says. “MR is complex and it requires both the physicist and the radiation oncologist to have this knowledge before it is possible to take full advantage of MR in RT.” Hence close collaboration with radiologists is essential.

In general, Professor Nyholm believes the benefits of MR in RT outweigh any remaining educational gaps. “The quality of the imaging data is really phenomenal,” he says.

**“RT is almost entirely an image-driven specialty. The importance of MR imaging will increase and start to impact RT in other ways, such as how we shape the treatment beams and position and treat the patient.”**

*Professor Tufve Nyholm*



#### References

1. Dimopoulos J, Petrow P, Tanderup K, et al. Recommendations from Gynaecological (GYN) GEC-ESTRO Working Group (IV): basic principles and parameters for MR imaging within the frame of image based adaptive cervix cancer brachytherapy. *Radiother oncol.* 2012;103(1):113-22.
2. Lundman JA, Bylund M, Garpebring A, Karlsson CT, Nyholm T. Patient-induced susceptibility effects simulation in magnetic resonance imaging. *Phys Imag Radiat Oncol.* 2017; 41-47. <http://dx.doi.org/10.1016/j.phro.2017.02.004>.
3. Persson E, Gustafsson C, Norström F, et al. MR-OPERA—A Multi-center/multi-vendor validation of MRI-only prostate treatment planning using synthetic CT images. *Int J Radiat Oncol Biol Phys.* 2017 Jun 16. pii: S0360-3016(17)31055-6. doi: 10.1016/j.ijrobp.2017.06.006. [Epub ahead of print]