



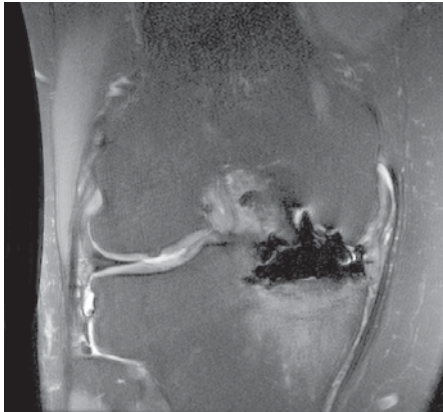
# New Tools in MR Upgrade Expand Imaging Capabilities and Increase Clinical Confidence

For many healthcare facilities, staying competitive in medical imaging requires an investment in advanced equipment. "Our Signa HDx 3.0T was highly advanced and fully-loaded when we installed the system," says John Sowers, MD, medical director at The Imaging Center of Pensacola (ICP). And, it remains advanced today thanks to the continuum upgrade path for the Signa line of MR scanners.

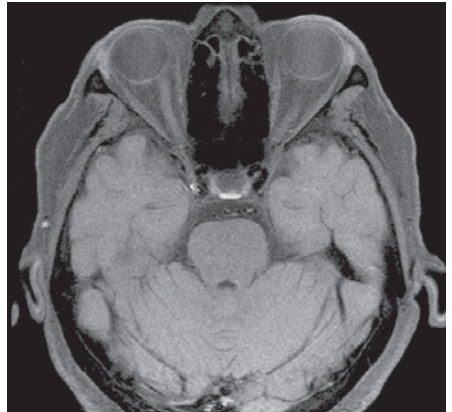
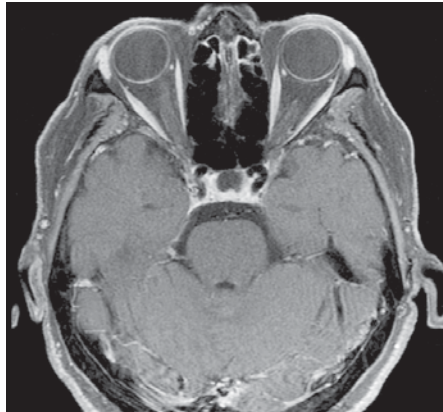
Dr. Sowers is always interested in new applications that will enhance image quality and enable his center to attract new patient cases or increase throughput. A GE MRI customer since the mid 1990s, he recently upgraded ICP's scanner with the latest ContinuumPak Version 15.0 upgrade.

"This is by far one of the best upgrade packages I've ever seen," adds Dr. Sowers.

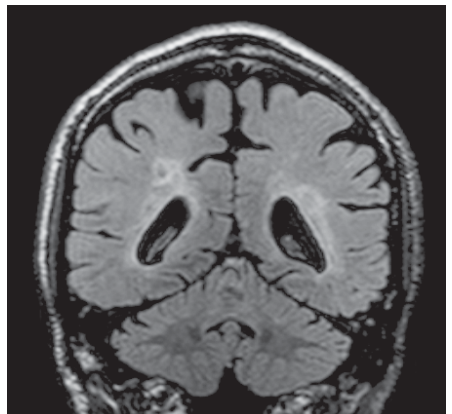
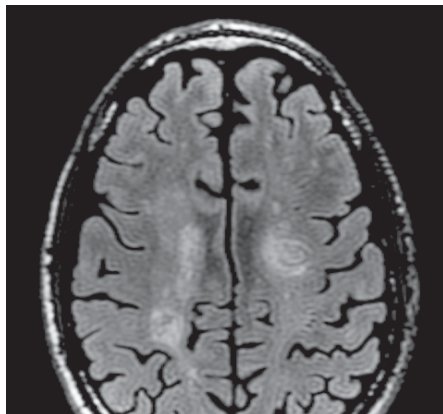
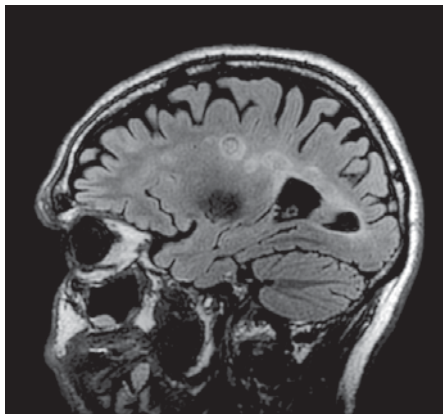
ContinuumPak 15.0 includes parallel imaging and Host enhancements. It also adds ARC™, 3D Dual Echo, and BrainSTAT techniques. Yet, it is the optional applications – specifically IDEAL, Cube, SWAN, and Inhance NCE MRA Suite – that Dr. Sowers finds most beneficial.



**Figure 1.** Proton Density IDEAL water images demonstrating excellent fat suppression despite hemiarthroplasty.



**Figure 2.** Pre- and Post-contrast T1 IDEAL water images. Note the robust fat suppression around air/tissue interfaces.



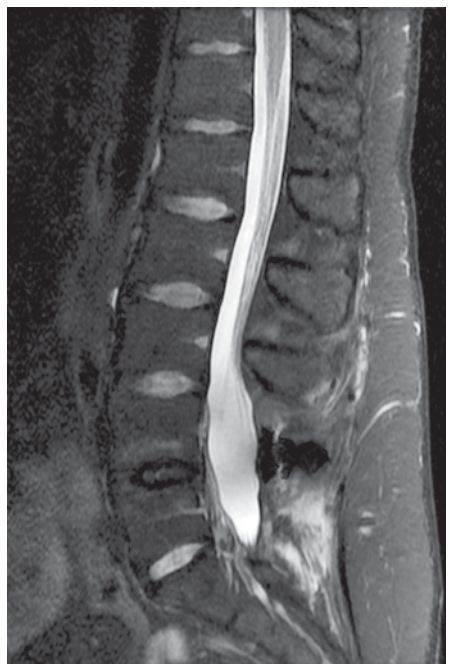
**Figure 3.** Sagittal Cube FLAIR with axial and coronal reformats showing MS plaques.

“As a package, this upgrade is more impressive than if each application is offered separately,” says Dr. Sowers. He feels more confident of his diagnosis and also believes that the images will help instill greater referring physician confidence in his analysis.

Acquiring uniform fat suppression is often a big challenge in MR imaging. “IDEAL, particularly for MSK imaging, cannot be underestimated,” says Dr. Sowers. He believes this application has the greatest impact on image quality in his practice. “It works very well with even the most challenging anatomy, such as the orbits or around metal implants. IDEAL helps reduce artifacts and enables reproducible uniform fat suppression, which results also in fewer repeat scans.”

Another critical component of IDEAL for ICP is the ability to generate water only and fat only images without running additional STIR or fat suppressed T2-weighted sequences. “It’s a double win with high image quality, IQ more diagnostic information, and the ability to increase patient throughput,” says Dr. Sowers.

Cube also helps improve patient throughput by eliminating a second acquisition in neuro studies. “We acquire Cube T2 FLAIR in the sagittal plane then reconstruct diagnostic-quality axial images,” he explains. With multi-planar reconstruction, he can also view the anatomy in coronal and oblique planes.



**Figure 4.** IDEAL T2 water images shows surgical site without loss of fat suppression around metallic implant.

The sagittal T2 FLAIR generates thinner slices than a 2D T2 FLAIR, he adds, and acquiring the entire volume with no gaps between slices helps increase diagnostic confidence. "I can see small, conspicuous lesions with Cube with excellent image contrast. This is a remarkable achievement." At ICP, Cube replaced 2D acquisitions for all neuro cases.


Another neuro application, SWAN, clearly depicts microbleeds and iron deposits. It can also help aid in diagnosing neurological disorders such as Parkinson's, Alzheimer's, multiple sclerosis, and stroke. "SWAN makes the stigmata from prior bleed very obvious," says Dr. Sower. "It is a great improvement, because in the past microbleeds have been difficult to visualize in a conspicuous way and I had to convince my referring physicians about their presence." Recently, he was able to easily view a small cryptic arterial venous malformation that had a small hemorrhage.

With the Inhance NCE MRA suite, ICP has an option for referring physicians and patients concerned about nephrogenic systemic fibrosis/nephrogenic fibrosing dermopathy (NSF/NFD). "Image quality with Inhance is amazingly good," says Dr. Sowers, "and we have the added advantage of repeating the sequence if needed because there is no intravenous contrast." The application is used at ICP for carotid bifurcation and whole neck studies.

Dual echo body imaging at 3.0T is more challenging. Typically, the in-phase echo has a longer TE than is desired while the out-of-phase TE is very short, and two acquisitions are necessary to acquire the images. This time penalty and the added chance for mis-registration of the two acquisitions from breathing artifacts made these studies impractical at 3.0T, until now.

3D Dual Echo solves this issue. "Dual echo improved the ability to perform body imaging at 3.0T with this sequence," says Dr. Sowers. He has used it to evaluate the lipid content in adrenal masses and look for fatty tissue changes in the liver.

"Rev15 has tools to help me approach my most challenging imaging situations," he continues, "which is very important to us since that is precisely our market niche." Armed with his 3.0T scanner and Rev15 upgrade, Dr. Sowers feels confident that he can answer almost any diagnostic imaging question that comes through the door. ■



Dr. John Sowers

John Charles Sowers, MD, is the medical director of the Imaging Center of Pensacola. He received his doctor of medicine from Bowman Gray School of Medicine, Wake Forest University, and completed his residency in diagnostic radiology and fellowship in interventional and vascular radiology at North Carolina Baptist Hospital.

#### About the facility

Founded in 1997, the Imaging Center of Pensacola offers advanced diagnostic imaging services with its arsenal of GE technology, including Signa HDx 3.0T and Signa HDe 1.5T MR scanners, a BrightSpeed Select16 CT scanner and Logiq 9 ultrasound. The center specializes in musculo-skeletal MR imaging, neurology, sports medicine and MR arthrography. The center is distinguished as a GE national show site and at RSNA 2007, Dr. Sowers received an award from GE for 10 years of imaging excellence service.

Known for quality imaging, ICP operates with two radiologists on-site at all time, seven technologists, two sonographers and 14 supporting staff.

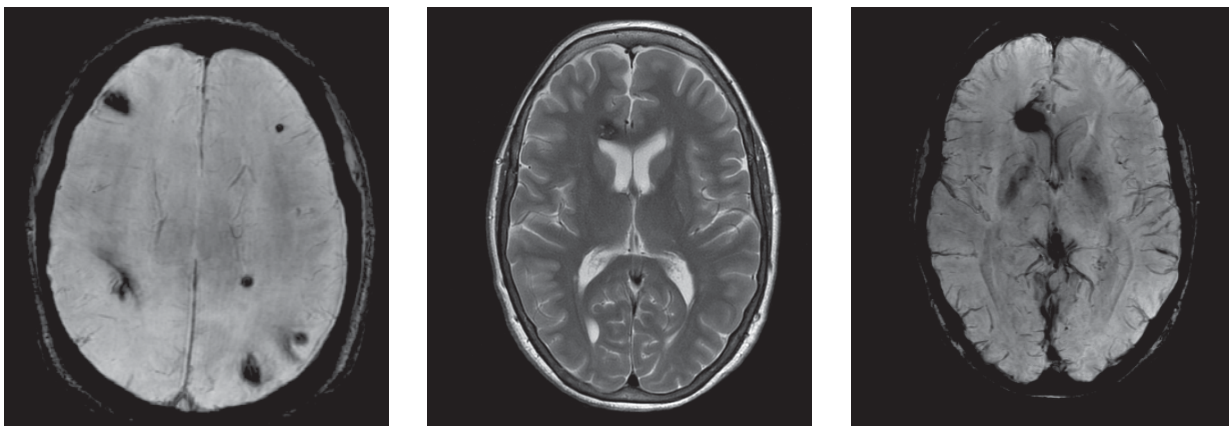


Figure 5. SWAN images clearly depict the presence of microbleeds.